

Case Report

An Innovative Technique for Fractured File Retrieval in a Mandibular Molar with Apical Periodontitis: A Case Report

Hadi Assadian¹, Mohsen Aminsobhani², Ziba Ghorvei Nossrat^{3*} 

¹ Assistant Professor, Department of Endodontics, School of Dentistry, Tehran University of Medical Sciences, Tehran, Iran

² Professor of Endodontics, Department of Endodontics, School of Dentistry, Tehran University of Medical Sciences, Tehran, Iran

³ Department of Endodontics, School of Dentistry, Tehran University of Medical Sciences, Tehran, Iran

* Corresponding Author: Ziba Ghorvei Nossrat, Email: Zibaghn90@gmail.com

DOI: 10.34172/jida.2286

Abstract

Background and Aim: Fractured file retrieval in endodontics remains a significant clinical challenge, particularly in anatomically complex root canal configurations. Retained instruments in infected canals reduce treatment success by 20–30%, necessitating removal despite procedural risks such as dentinal loss and perforation.

Case Report: A 35-year-old female presented with symptomatic apical periodontitis in a mandibular first molar. During root canal preparation, a rotary file fractured in the mesiobuccal canal's apical third. Conventional retrieval methods failed, prompting the use of a novel hydraulic pressure-assisted technique combining ultrasonic vibration with controlled irrigation via an adjacent canal. The fractured file was successfully dislodged with minimal dentin loss. A four-month follow-up showed significant healing.

Conclusion: This technique offers a less invasive, effective alternative to traditional retrieval methods. Its success highlights the potential for improved endodontic outcomes while preserving tooth structure. Further research is needed to assess its broader applicability.

Key Words: Fractured file retrieval, mandibular molar, apical periodontitis, endodontic instrument removal, novel technique

Received: 8 March 2026 | Accepted: 19 May 2026 | ePublished: Winter and Spring 2026; Vol. 38, No. 1-2

Introduction

The management of separated endodontic instruments (SEIs) remains one of the most technically demanding challenges in endodontics, where clinicians must navigate the delicate balance between microbial removal and structural preservation. With over 15 million endodontic procedures performed annually, according to American Association of Endodontics data (1), the probability of instrument fracture is substantial, occurring in 0.25%–6% of cases involving hand instruments and 0.4%–5% of rotary nickel-titanium (NiTi) procedures (2, 3). This complication carries significant prognostic implications: while retained fragments in non-infected canals demonstrate outcomes comparable to standard treatments when

properly sealed (4), their presence in infected cases reduces periapical healing rates by 20%–30% due to compromised debridement and persistent infection (5, 6). The introduction of NiTi rotary systems, despite revolutionizing canal preparation efficiency, has paradoxically amplified fracture risks through cyclic fatigue accumulation and torsional stress concentration, particularly in curved canals (7, 8).

Anatomically driven differences in retrieval success underscore the complexity of SEI management. Apical fragments in mandibular molars demonstrate ≤43% removal rates, contrasting with 48%–95% success for coronal-third fragments in maxillary anterior teeth (4, 9). This disparity results from access limitations related to root curvature, where fragments lodged beyond a canal curvature exhibit

12%–18% retrieval probabilities versus 32%–76% in straight segments (10, 11). The relationship between the fragment and the canal wall further dictates outcomes: the presence of a distinct gap simplifies retrieval attempts, whereas adherent fragments in narrow, calcified canals often necessitate aggressive dentin removal (12, 13).

Conventional retrieval methodologies employ a three-step strategic approach: ultrasonic reshaping under dental operating microscope (DOM) magnification, mechanical grasping systems, and guided bypass protocols. Ruddle's ultrasonic technique, considered the gold standard, requires precise circumferential dentin removal (0.81–1.23 mm³ volume loss) using modified Gates-Glidden burs and specialized tips (11, 14). While effective, this method carries inherent risks of procedural errors such as perforations (5%–8% incidence) and secondary fractures, particularly in curved canals (8). Mechanical systems like the Terauchi File Retrieval Kit (TFRK) and Endo Rescue Kit aim to minimize dentin sacrifice through microtube engagement and screw-mediated fragment capture, though their efficacy remains constrained by the need for 1–2 mm of coronal fragment exposure (13, 15). Bypass attempts, though preferable for structural preservation, introduce new risks including ledge formation (12%–18%) and canal transportation, particularly in severely curved root systems (4, 11).

The emerging paradigm emphasizes minimally invasive retrieval strategies that prioritize dentin conservation while ensuring complete debridement. Recent studies demonstrate that exceeding 1.5 mm³ of dentin loss during retrieval increases long-term fracture susceptibility by 3.2-fold, establishing strict removal thresholds (16). Simultaneously, microbial infection cannot be overlooked: retained fragments in infected canals create inaccessible niches for *Enterococcus faecalis* and *Candida albicans* biofilms, directly compromising disinfection efficacy (17, 18). This dilemma necessitates case-specific decision algorithms that consider fragment location, periapical status, and operator expertise (8, 19).

This case report details the successful application of a novel hydraulic pressure protocol in a high-complexity scenario involving a firmly adherent apical fragment, demonstrating the technique's potential to redefine SEI management paradigms.

Case Presentation

Patient Information

A 35-year-old female presented with a chief complaint of spontaneous pain and localized swelling in the buccal region adjacent to the left mandibular first molar. The patient's medical history was non-contributory, with no significant systemic diseases or medications reported. Her dental history included routine restorative care, though the mandibular left first molar had not been previously treated.

Informed Consent

Written informed consent was obtained from the patient for the publication of this case report and accompanying images.

Clinical Findings

Extraoral examination revealed no significant findings. Intraoral examination revealed a fluctuant swelling in the buccal vestibule adjacent to the mandibular left first molar. The affected tooth exhibited no sensitivity to cold or percussion but demonstrated tenderness to palpation. Periodontal probing depths were within normal limits (≤ 3 mm) throughout. Prior to the consultation, cone-beam computed tomography (CBCT) imaging had been ordered by the referring clinician, and the patient provided these images during the initial evaluation (Figure 1). Periapical (PA) radiography identified a deep mesial carious lesion resulting in pulpal involvement, alongside apical periodontitis with cystic-appearing changes predominantly affecting the distal root (Figure 2).

Timeline

The patient's clinical course is summarized chronologically below:

- **Initial Presentation:** Patient presented with spontaneous pain and swelling.
- **Session 1 (Day 0):** Access cavity preparation, chemomechanical preparation, instrumentation with NaOCl irrigation, and intracanal calcium hydroxide placement. Incision and drainage of buccal swelling was performed.
- **Session 2 (Week 3):** Temporary restoration removed; calcium hydroxide evacuated. During this procedure, an F3 rotary instrument fractured in the apical third of

the mesiobuccal canal. Partial bypass of the fragment was achieved.

- **Session 3 (Week 4):** Attempted fragment retrieval using ultrasonic vibration and a mechanical extraction kit was unsuccessful.
- **Session 4 (Week 5):** Successful fragment retrieval using a hydraulic pressure-assisted ultrasonic technique, followed by canal obturation.
- **Follow-up (Month 2):** Clinical and radiographic evaluation demonstrated healing.

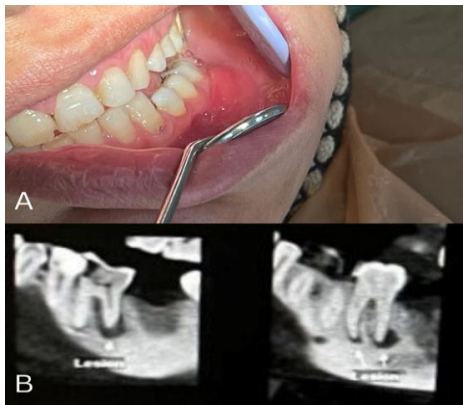

Figure 1. A) Clinical photograph showing swelling in the buccal mucosal fold adjacent to the left mandibular first molar. B) Sagittal CBCT section revealing a radicular lesion associated with the tooth

Diagnostic Assessment

Based on the clinical and radiographic findings, a definitive diagnosis of necrotic pulp with an acute apical abscess was established. Diagnostic testing included:

- **Sensitivity Testing:** Absence of response to cold and electric pulp testing confirmed pulp necrosis.
- **Palpation/Percussion:** Tenderness to palpation in the buccal vestibule; no percussion sensitivity.
- **Radiographic Assessment:** Periapical radiography and CBCT imaging confirmed the presence of apical periodontitis with periapical radiolucency involving the distal root, and a deep mesial carious lesion extending to the pulp chamber.

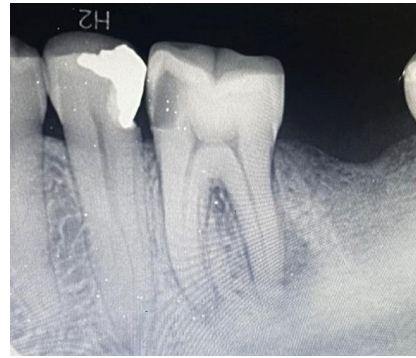


Figure 2. Initial PA reveals an active lesion adjacent to the roots.

Therapeutic Intervention

All procedures were performed under an operating microscope following administration of inferior alveolar nerve block anesthesia (lidocaine 2% with 1:80,000 epinephrine), supplemented by buccal infiltration.

- **Initial Treatment (Session 1):** Access cavity preparation was completed. Canals were negotiated with a #10 K-file and instrumented using rotary NiTi instruments (M-Taper, IMD, China) under copious irrigation with 5.25% NaOCl and normal saline. Calcium hydroxide paste (Calcium Hydroxide Powder, Golchai, Iran) was placed as an intracanal medicament. The cavity was sealed with temporary filling (Zonalin, ZOE T, DentaFlux, Spain). Incision and drainage of the buccal swelling was performed, yielding serous exudate (Figure 3).

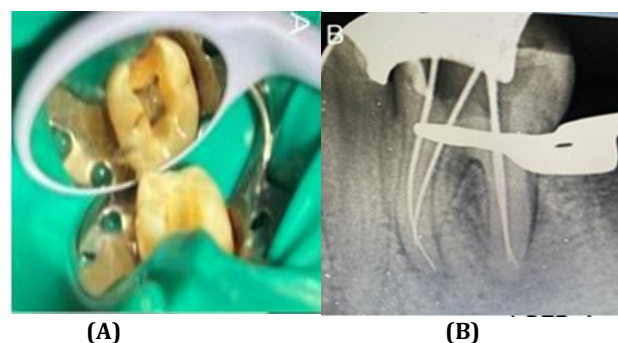


Figure 3. A) After completing the access, four orifices were identified. B) The initial File radiography indicates that the mesial root canals are classified as Type 2.

- **Fracture Event and Initial Management (Session 2, Week 3):** Following removal of the temporary restoration and evacuation of calcium hydroxide with rotary files and 5.25% NaOCl irrigation, an F3 rotary instrument fractured in the apical third of the mesiobuccal canal. Periapical radiographs confirmed the fragment's position within the canal curvature (Figure 4). Partial bypass was achieved using a pre-curved #06 C-Pilot file.

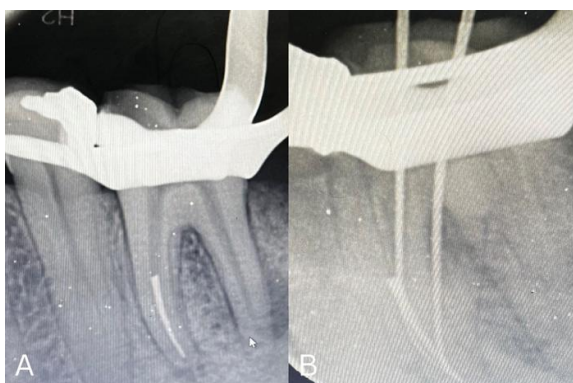


Figure 4. A) Fractured rotary file completely obstructs the mesiobuccal canal's apical third. B) A successful bypass of the fractured file was obtained during the same session

- **Subsequent Retrieval Attempts (Session 3, Week 4):** Circumferential dentin removal was attempted using a DTE ultrasonic tip #6 (DTE, Woodpecker, China) at 30% power; however, the fragment remained adherent. The BTEX mechanical extraction kit (Daimotech, Iran) was also unsuccessful due to insufficient coronal fragment exposure. The canal was temporarily medicated with calcium hydroxide and sealed with Cavit (Coltene, Aria Dent, Iran).
- **Hydraulic Pressure-Assisted Retrieval (Session 4, Week 5):** A hydraulic pressure-assisted technique was employed. A DTE ultrasonic tip #6 was placed in direct contact with the fragment and activated at 30% power. Concurrently, an irrigation needle (30G, EndoArt, Turkey) was positioned in the adjacent mesiolingual canal, delivering normal saline under pressure. This combination of hydraulic

force and ultrasonic energy successfully dislodged the fragment, which was expelled from the canal during irrigation.

- **Finalization:** Following fragment removal, canal instrumentation was completed. Obturation was performed using cold lateral compaction with gutta-percha 2% (MetaBiomed, Korea). Neosealer (Avalon Biomed, USA) was used in the mesial canals, and Dia-proseal (DiaDent, Korea) in the distal canal (Figure 5).

Follow-up and Outcomes

At the two-month postoperative recall, clinical examination revealed complete resolution of buccal swelling with restored mucosal contour. Periodontal parameters remained within physiological limits (probing depth 3 mm; no pathological mobility, Miller's Grade 0). Radiographic evaluation demonstrated evidence of periapical healing, characterized by a significant reduction in radiolucency dimensions and trabecular bone reorganization (Figure 6).

Patient Perspective

The patient reported significant relief from preoperative symptoms and expressed satisfaction with the clinical outcome and the preservation of her natural tooth




Figure 5. A) Complete removal of the fractured file was successfully achieved using the hydraulic pressure approach, showcasing its effectiveness in resolving complex endodontic challenges. B) After file removal, complete obturation of the root canals was accomplished

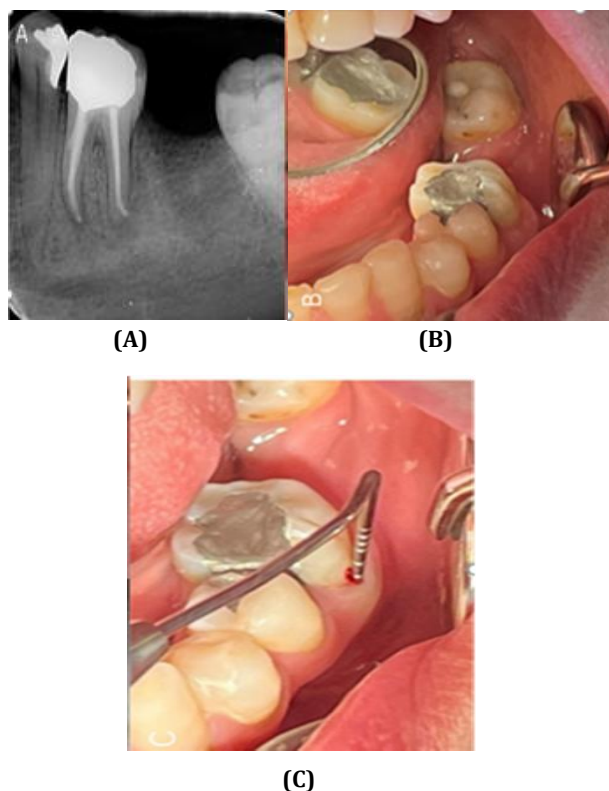


Figure 6. A) Initial PA demonstrating resolved periapical lesion, B) Clinical view showing intact buccal mucosa and healthy gingival margins, C) Periodontal probing (3 mm) and BOP

Discussion

This case report describes the successful retrieval of an SEI from the apical third of a mandibular molar using a novel hydraulic pressure-assisted ultrasonic technique. The procedure achieved fragment removal with minimal dentin loss following unsuccessful attempts with conventional ultrasonic vibration and a mechanical extraction kit. Two-month follow-up demonstrated favorable periapical healing, supporting the potential clinical utility of this approach.

The retrieval of SEIs remains a significant clinical challenge, with conventional methods such as ultrasonic tips, micro forceps, and specialized retrieval kits like the Terauchi File Retrieval Kit (TFRK) mainly relying on mechanical manipulation (20, 21). While these techniques have demonstrated varying degrees of success, they frequently require substantial dentin removal to access SEIs, thereby

increasing the risk of iatrogenic complications, including root perforation (21, 22). Time efficiency varies considerably across different methods and studies (23), with prolonged procedural durations potentially limiting clinical practicality (24). The risk of procedural errors, including perforations, canal transportation, and craze line formation, remains a constant concern with ultrasonic techniques (25), highlighting their technique-sensitive nature (26). Anatomical considerations play a pivotal role in retrieval outcomes, with canal curvature representing a particularly significant factor; success rates are markedly higher in canals with curvature radii exceeding 4.4 mm (23). SEI location similarly influences prognosis, as retrieval proves more predictable in coronal and middle thirds compared to apical segments (27). Canal morphology further impacts procedural difficulty, as increased file length and greater canal curvature have been associated with extended retrieval times (28). In the present case, the fragment was located in the apical third of a curved mesiobuccal canal, representing a high-complexity scenario consistent with published predictors of reduced retrieval success.

In this context, the hydraulic pressure-assisted [technique offers several distinct advantages. First, it resulted in significantly reduced dentin loss [compared to conventional methods such as Ruddle's technique or TFRK (11). This benefit stems from the synergistic effects of ultrasonic vibrations and hydraulic pressure, which disrupt fragment-dentin adhesions while generating hydrodynamic forces to dislodge the fragment without aggressive circumferential dentin removal. Second, the decreased procedural duration relative to techniques employing burs or micro forceps (29) enhances clinical practicality. Third, by utilizing existing access pathways through an adjacent canal for irrigation delivery, the method preserved critical dentin structure that would otherwise require sacrifice for direct fragment access.

Despite these advantages, several limitations warrant consideration. The technique required the presence of an accessible adjacent canal for irrigation delivery, a condition not present in all clinical scenarios, such as single-canaled teeth. Additionally, while normal saline was used to minimize tissue irritation, the potential for irrigant extrusion beyond the apex, though minimized by

controlled flow rates, cannot be entirely excluded. Clinical validation of this technique remains limited, particularly regarding its efficacy in severely curved canals and long-term structural outcomes. The present report represents a single case with short-term follow-up, precluding definitive conclusions about broader applicability.

Against this clinical landscape, hydraulic pressure-assisted retrieval emerges as a promising modality combining ultrasonic energy with controlled fluid dynamics. By utilizing existing access pathways through adjacent canals, the method theoretically preserves critical dentin structure while achieving fragment dislodgement. This innovative approach aligns with the current professional emphasis on minimizing invasive interventions without compromising clinical efficacy (29), suggesting potential for incorporation into future treatment protocols as experience with the technique accumulates and its applications become more clearly defined through additional research. Further research is needed to assess the broader applicability of this technique. Prospective studies with larger sample sizes, extended follow-up periods, and comparative designs against conventional retrieval methods would help establish its relative efficacy and safety. Investigation of optimal irrigation parameters, including flow rates, needle types, and irrigant selection, may further refine the technique and expand its clinical indications.

Conclusion

This case report demonstrates a novel hydraulic pressure-assisted technique for SEI retrieval in a mandibular molar with apical periodontitis. The approach successfully addressed challenges posed by conventional methods while ensuring minimal dentin loss and optimal healing outcomes. Further studies are warranted to validate its efficacy across various clinical scenarios.

Declarations

Declaration of Ethical Considerations

The authors confirm that written informed consent was obtained from the patient for the publication of this case report, including any accompanying images,

clinical details, and paraclinical data. The patient has been anonymized to ensure privacy, and no identifiable personal information is disclosed.

Conflict of Interest Statement

The authors declare that they have no conflict of interest related to this study.

Funding Statement

This research did not receive any specific grant from funding agencies in the public, commercial, or not-for-profit sectors.

Informed Consent

Written informed consent was obtained from the patient for the publication of this case report and any accompanying images.

Authors' Contributions

Hadi Assadian (HA) and **Mohsen Aminsobhani (MA)** contributed to the conception, design, and supervision of the case report, provided critical revision of the manuscript, and approved the final version. **Ziba Ghorvei Nossrat (ZGN)** performed the clinical procedure (fractured file retrieval in the mandibular molar), contributed to data collection, literature review, drafting of the manuscript, and final approval. All authors read and approved the final manuscript.

Declaration of Generative Artificial Intelligence (AI) Utilization

During the preparation of this work, the authors used an artificial intelligence-assisted language model (Claude 3.5 Sonnet, Anthropic) exclusively for language editing, grammar correction, and formatting assistance to improve readability and ensure compliance with journal style guidelines. The AI tool was not used to generate scientific content, interpret data, draw conclusions, or create original intellectual contributions. Following the use of this tool, the authors thoroughly reviewed and revised the content as needed and assume full responsibility for the final manuscript's accuracy, originality, and integrity. No AI technologies were used in the creation or manipulation of clinical images or figures.

References

1. Chew T, Brennan D, Rossi-Fedele G. Comparative longitudinal study on the impact root canal treatment and

- other dental services have on oral health-related quality of life using self-reported health measures (Oral Health Impact Profile-14 and global health measures). *J Endod.* 2019;45(8):985-93. e1.
2. Tzanetakakis GN, Kontakiotis EG, Maurikou DV, Marzelou MP. Prevalence and management of instrument fracture in the postgraduate endodontic program at the Dental School of Athens: a five-year retrospective clinical study. *J Endod.* 2008;34(6):675-8.
 3. Fu M, Zhang Z, Hou B. Removal of broken files from root canals by using ultrasonic techniques combined with dental microscope: a retrospective analysis of treatment outcome. *J Endod.* 2011;37(5):619-22.
 4. Ingle, J.I. and Beveridge, E.E. (1985) *Endodontics*. 3rd edn. Philadelphia: Lea & Febiger.
 5. Nevares G, Cunha RS, Zuolo ML, da Silveira Bueno CE. Success rates for removing or bypassing fractured instruments: a prospective clinical study. *J Endod.* 2012; 38(4):442-4.
 6. Hindlekar A, Kaur G, Kashikar R, Kotadia P. Retrieval of separated intracanal endodontic instruments: a series of four case reports. *Cureus.* 2023;15(3):e35694.
 7. Terauchi Y, Ali WT, Abielhassan MM. Present status and future directions: removal of fractured instruments. *Int Endod J.* 2022;55 Suppl 3:685-709.
 8. Portigliatti R, Consoli Lizzi EP, Rodríguez PA. Predictive factors in the retrieval of endodontic instruments: the relationship between the fragment length and location. *Restor Dent Endod.* 2024; 49(4): e35.
 9. Alamoudi RA, Alfarran A, Alnamakani B, Howait M, Alghamdi NS, Ain TS. Assessment of incidence, management and contributory factors of root canal instrument separation in an endodontics post-graduate program: a retrospective clinical study. *Niger J Clin Pract.* 2024;27(1):16-21.
 10. Iqbal MK, Kohli MR, Kim JS. A retrospective clinical study of incidence of root canal instrument separation in an endodontics graduate program: a PennEndo database study. *J Endod.* 2006;32(11):1048-52.
 11. Abdeen MA, Plotino G, Hassanien EE, Turkey M. Evaluation of dentine structure loss after separated file retrieval by three different techniques: an ex-vivo study. *Eur Endod J.* 2023;8(3):225-30.
 12. Shen Y, Peng B, Cheung GS. Factors associated with the removal of fractured NiTi instruments from root canal systems. *Oral Surg Oral Med Oral Pathol Oral Radiol Endod.* 2004;98(5):605-10.
 13. Madarati AA, Hunter MJ, Dummer PM. Management of intracanal separated instruments. *J Endod.* 2013; 39(5): 569-81.
 14. Ruddle CJ. Nonsurgical retreatment. *J Endod.* 2004; 30 (12):827-45.
 15. Terauchi Y, O'Leary L, Suda H. Removal of separated files from root canals with a new file-removal system: case reports. *J Endod.* 2006;32(8):789-97.
 16. Smoljan M, Hussein MO, Guentsch A, Ibrahim M. Influence of progressive versus minimal canal preparations on the fracture resistance of mandibular molars: a 3-dimensional finite element analysis. *J Endod.* 2021;47(6):932-8.
 17. Lin LM, Rosenberg PA, Lin J. Do procedural errors cause endodontic treatment failure? *J Am Dent Assoc.* 2005;136(2):187-93.
 18. Zahran SS. Impact of anatomical and clinical variables on the success of endodontic instrument fragment retrieval. *J Oral Sci.* 2025;67(1):5-9.
 19. Nevares G, Cunha RS, Zuolo ML, Bueno CE. Success rates for removing or bypassing fractured instruments: a prospective clinical study. *J Endod.* 2012;38(4):442-4.
 20. Meidyawati R, Suprastiwi E, Setiati HD. Broken file retrieval in the lower right first molar using an ultrasonic instrument and endodontic micro forceps. *Case Rep Dent.* 2019; 2019:7940126.
 21. Pruthi PJ, Nawal RR, Talwar S, Verma M. Comparative evaluation of the effectiveness of ultrasonic tips versus the Terauchi file retrieval kit for the removal of separated endodontic instruments. *Restor Dent Endod.* 2020; 45(2): e14.
 22. Gupta R, Sharma T, Charles N, Bedi R. Clinical approach to the management of fractured instruments using ultrasonics and the instrument retrieval system under the dental operating microscope. *Int J Med Biomed Stud.* 2020; 4:116-21.
 23. Alomairy KH. Evaluating two techniques on removal of fractured rotary nickel-titanium endodontic instruments from root canals: an in vitro study. *J Endod.* 2009 Apr 1; 35 (4):559-62.
 24. Garg H, Grewal MS. Cone-beam computed tomography volumetric analysis and comparison of dentin structure loss after retrieval of separated instrument by using ultrasonic EMS and ProUltra tips. *J Endod.* 2016; 42(11): 1693-8.
 25. Cujé J, Bargholz C, Hülsmann M. The outcome of retained instrument removal in a specialist practice.

Int Endod J. 2010;43(7):545-54.

26. Karim MH, Faraj BM. Comparative evaluation of a dynamic navigation system versus a three-dimensional microscope in retrieving separated endodontic files: an in vitro study. J Endod. 2023;49(9):1191-8.

27. Mohamed AA, Plotino G, Hassanien EE, Turkey M. Evaluation of dentine structure loss after separated file retrieval by three different techniques: an ex-vivo study. Eur Endod J. 2023;8(3):225-30.

28. Terauchi Y, Seijo C, Bogen L, Bogen G. Factors affecting the removal time of separated instruments. J Endod. 2021; 47(8):1245-51.

29. Pruthi PJ, Nawal RR, Talwar S, Verma M. Comparative evaluation of the effectiveness of ultrasonic tips versus the Terauchi file retrieval kit for the removal of separated endodontic instruments. Restor Dent Endod. 2020; 45(2): e14.

30. Gencoglu N, Helvacioğlu D. Comparison of the different techniques to remove fractured endodontic instruments from root canal systems. Eur J Dent. 2009;3(2):90-5.