

# Position of maxillary premolars relative to the maxillary sinus floor and alveolar bone in an Iranian population: A CBCT study

Shirin Sakhdari <sup>1</sup> , Mahsa Khademi <sup>2</sup>, Marzieh Tatina <sup>3</sup>

<sup>1</sup> Associate Professor, Oral and Maxillofacial Radiology Department, Faculty of Dentistry, Tehran Medical Science, Islamic Azad University, Tehran, Iran

<sup>2</sup> Assistant Professor, Oral and Maxillofacial Radiology Department, Faculty of Dentistry, Tehran Medical Science, Islamic Azad University, Tehran, Iran

<sup>3</sup> Dentist, Private Practice, Tehran, Iran

## Abstract

**Background and Aim:** The aim was to assess the position of maxillary premolars relative to the maxillary sinus floor and alveolar bone in an Iranian population using cone-beam computed tomography (CBCT).

**Materials and Methods:** This descriptive study evaluated 150 maxillary first and second premolars. The alveolar bone width at the bone crest and the angle between the longitudinal axis of the teeth and the longitudinal axis of the alveolar bone were measured. The relationship between the maxillary premolars and the maxillary sinus floor was categorized into five types. The effect of age, sex and side of the jaw was also statistically analyzed. Data were analyzed using t-test, Fisher's exact test, and Pearson's correlation coefficient with 95% confidence interval.

**Results:** The mean alveolar bone thickness was  $9.8 \pm 1.3$  mm at the site of premolars, and the mean internal angle was  $1.19 \pm 6.3$  degrees. The most common type of root connection with the sinus floor was type 2 in both first and second premolars (39.1% and 53.4%, respectively), but no significant difference was observed in the frequency of different types ( $P > 0.05$ ). There was no significant relationship between different types and alveolar bone thickness, but the mean size of internal angle was larger in type 1 ( $P = 0.04$ ). No significant association was detected between types and gender, age or side of the jaw ( $P > 0.05$ ).

**Conclusion:** The results of the present study may be useful for dental procedures at the site of premolars in absence of 3D imaging.

**Key Words:** Tooth root; Posterior teeth; Maxillary Sinus; Alveolar Bone; Cone-Beam Computed Tomography

 Corresponding author:  
Shirin Sakhdari, Associate  
Professor, Oral and  
Maxillofacial Radiology  
Department, Faculty of  
Dentistry, Tehran Medical  
Science, Islamic Azad  
University, Tehran, Iran

sh.sakhdari@yahoo.com

Received: 7 July 2023  
Accepted: 20 Oct 2023

➤ **Cite this article as:** Sakhdari SH, Khademi M, Tatina M. Position of maxillary premolars relative to the maxillary sinus floor and alveolar bone in an Iranian population: A CBCT study. J Iran Dent Assoc. 2023; 35(3-4):44-51.

## Introduction

Anatomical limitations related to the position of the maxillary sinus floor or suboptimal quality/quantity of the alveolar bone are among the main concerns in implant placement in the maxilla. The presence of molar and premolar teeth in the posterior region of the maxilla are very important, because long term

edentulousness in this region reduces bone volume and can shortens the life of implants inserted in the region (1). The maxillary alveolar ridge has a curved form in the anterior maxilla which changes towards the posterior areas. Maxillary premolars have a critical position in the maxillary arch due to the proximity of their apices to the maxillary sinus

floor. In previous studies, it has been observed that the angle of the alveolar bone and the position of the inferior wall of the maxillary sinus are very important because it affects the angle of implant placement (2).

The maxillary sinus is one of the most important vital organs in the face, which is located above the posterior teeth and is closely related to the maxillary posterior teeth and The maxillary sinus floor (MSF) is developed by the maxillary alveolar process. (3,4)

The relationship of the premolar roots with the maxillary sinus floor should be assessed in order to minimize the risks of implant insertion into the maxillary sinus. Procedural errors such as perforation of the sinus may occur during surgical intervention resulting in oroantral communication. Also odontogenic infection through molar and premolar teeth may migrate directly to the maxillary sinus through bone marrow, blood vessels and lymphatics, or perforations during root canal therapy as these can lead to maxillary sinusitis (2,3,4) In addition, knowledge about the exact location of the maxillary sinus floor is important to find the path of dental infections in endodontics and surgical procedures (5,6). Panoramic and intraoral imaging modalities do not usually provide adequate information about the buccal bone width, or the condition of three-dimensional anatomical structures at the target site (7).

Cone-beam computed tomography (CBCT) scans can be used to accurately measure the thickness of cancellous and cortical bones, with much lower patient radiation dose than computed tomography (CT). CBCT is commonly requested for patients requiring dental implant treatment. However, limited topographic studies have examined the width and height of the alveolar bone or the relationship of the maxillary molars and the maxillary sinus floor using CBCT (8-13). Also, few studies have investigated the relationship between premolar teeth and sinus floor in Iranian people, and if gender, age or jaw side, may affect the distance between root apex and maxillary sinus floor, and the variations of the angle of alveolar process in this region is also unclear because ethnicity may impact the anatomical relationship between maxillary molars and the maxillary sinus.

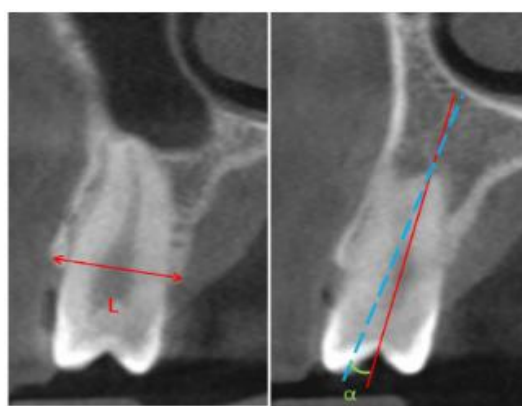
Due to the gap of information on this topic in the Iranian population, this study aimed to assess the relationship of the maxillary premolars with the maxillary sinus floor and the alveolar bone in an Iranian population.

## Materials and Methods

This descriptive study evaluated 150 maxillary premolars on CBCT scans of patients referred to a radiology clinic in Tehran. The CBCT scans had been obtained for diagnostic and therapeutic purposes not related to this study. The respective maxillary premolars had not undergone endodontic treatment and had no pathological lesion (radiolucent or radiopaque), or history of orthodontic treatment or trauma, and their antagonistic teeth were present in the opposite jaw. Also, there was no canine or first molar missing. Both males and females with similar age distribution were evaluated.

CBCT images had been obtained by the same CBCT scanner (Carestream; Kodak, France) and the measurements were made using On Demand software (Cybermed, Korea). The exposure settings included 10 mA, 90 kVp, and 0.180 mm voxel size.

Demographic information of patients (age, gender, type of tooth, and side of the jaw) and measurements made by the software on CBCT images were all recorded. The alveolar bone width was measured in millimeters, and the angle between the longitudinal axis of the tooth and the longitudinal axis of the alveolar bone was measured in degrees. Figure 1 shows the measurement of alveolar bone width and the internal angle (2).



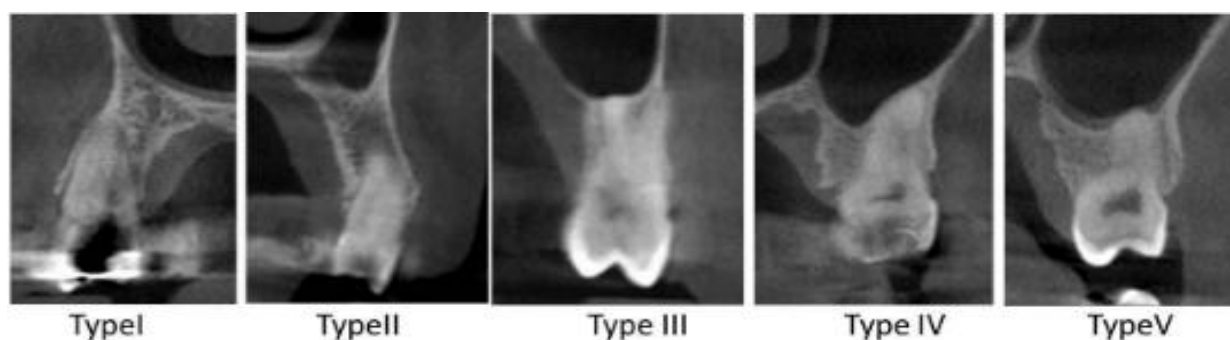
**Figure 1.** Measurement of alveolar bone width (L) and the internal angle (a) of maxillary premolars on cross-sectional CBCT images

The vertical relationship between the maxillary premolars and the maxillary sinus floor was divided into 5 types as follows:

- Type 1: The floor of the maxillary sinus is not seen above the root apex.
- Type 2: The floor of the maxillary sinus is located above the root apex.
- Type 3: The floor of the maxillary sinus is located at the level of the root apex, without an apical protrusion over the floor of the maxillary sinus.

- Type 4: The floor of the maxillary sinus is located below the level of the root apices, without an apical protrusion over the floor of the maxillary sinus, and the apex is seen in the buccal part of the inferior wall of the sinus.
- Type 5: Apical protrusions of the root apices are observed over the floor of the maxillary sinus. ( Figure 1)

Data were analyzed by t-test, Fisher's exact test, and Pearson's correlation coefficient with 95% confidence interval.



**Figure 2.** Vertical relationship of the maxillary sinus and the roots of the maxillary premolars classified into 5 types

## Results

A total of 150 premolars were examined. The mean age of the patients was  $44 \pm 12.1$  years. Fifty-nine patients (39.3%) were males and 91 patients (60.7%) were females. Among the premolars studied, 59 (39.3%) were in the right (29 first premolars and 30 second premolars) and 91 (60.7%) were in the left quadrant (63 first premolars and 28 second premolars). Ninety-two (61.3%) first premolars and 58 (38.7%) second premolars were evaluated.

The mean ( $\pm$  standard deviation) alveolar bone width in premolars was  $9.8 \pm 1.3$  mm; this value was  $9.9 \pm 1.4$  mm in the first premolars and  $9.8 \pm 1.1$  mm in the second premolars. There was no significant difference in alveolar bone thickness at the site of first and second premolars ( $P > 0.05$ ).

Also, the mean ( $\pm$  standard deviation) internal angle in premolars was  $19.1 \pm 6.3$  degrees, which was  $19.6 \pm 6.3$  degrees in the first premolars and  $18.2 \pm 6.1$  degrees in the second premolars. The internal angle in the first premolars was larger than that in the second

premolars. Information on the mean thickness and internal angle of the first and second premolars is presented in Table 1.

The vertical relationship between the apex of the premolars and the floor of the sinus was classified into 5 types. Table 2 presents the frequency of different types of vertical relationship of the maxillary first and second premolar roots with the maxillary sinus floor.

There was no significant difference in the relationship of teeth with the maxillary sinus floor between males and females, different age groups, or the right and left sides of the maxilla. There was no correlation between the internal angle and the type of relationship between the premolars and the maxillary sinus in the right or left side (except for type 1). Type 1 had the highest mean angle and type 3 had the lowest mean angle at both sides. Figure 3 shows the related comparison.

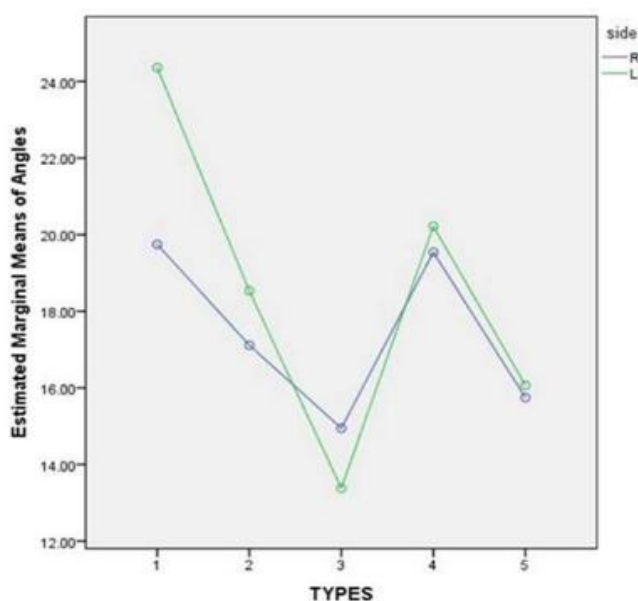
Alveolar bone width at the site of premolars was  $9.7 \pm 0.19$  mm in type 1,  $9 \pm 9.15$  mm in type 2,  $9.7 \pm 0.29$  mm in type 3,  $9.8 \pm 0.31$  mm in type 4, and  $10 \pm 4.47$  mm in type 5.

**Table 1.** Mean internal angle and alveolar bone thickness at the site of first and second premolars (P-values obtained by t-test)

	First premolars	Second premolars	P-value
<b>Number</b>	92	58	
<b>Thickness</b>	1.4 ± 9.9	1.1 ± 9.8	0.52
<b>Angle</b>	6.3°±19.6	6.1° ±18.2	0.20

**Table 2.** Frequency of different types of vertical relationship of the first and second premolars with the maxillary sinus floor (P-value obtained by Pearson's Correlation test)

	First premolars	Second premolars	P-value
<b>Number</b>	92	58	
<b>Type</b>			
<b>1</b>	31 (33.7%)	10 (17.2%)	
<b>2</b>	36 (39.1%)	31(53.4%)	
<b>3</b>	11 (12.0%)	8 (13.8%)	<b>0.04</b>
<b>4</b>	12 (13.0%)	4 (6.9%)	
<b>5</b>	2 (2.2%)	5(8.6%)	

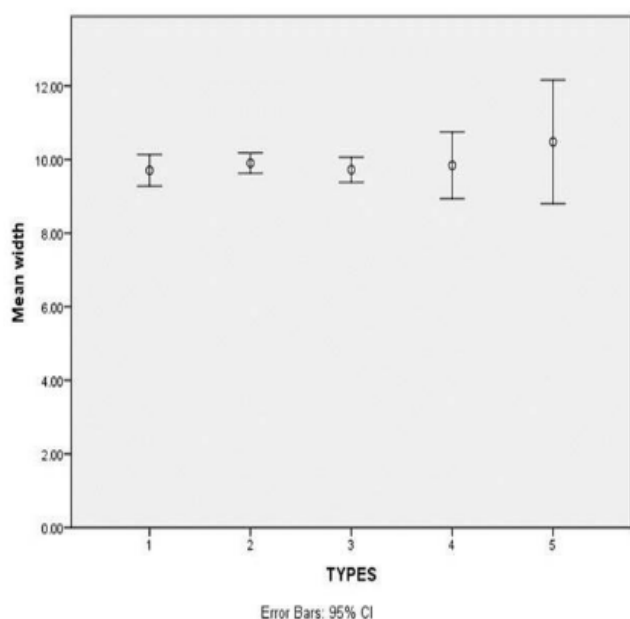
**Figure 3.** Comparison of the right and left sides of the maxilla regarding types of vertical relationship and the mean angle (blue line for the right and green line for the left side)

There was no significant difference in alveolar bone width between the 5 types ( $P = 0.63$ ). Based on the results, in type 2, the dispersion of data related to the mean bone width was very small and almost all cases of type 2 had the same alveolar bone width. With less precision, the bone width in types 1 and 3 was also within a certain range. In types 4 and 5, the dispersion of data was high compared with other types. Since the measurements of the types overlapped, it was not possible to distinguish the types from each other in terms of alveolar bone width. (Figure 4)

The internal angle in type 1 was larger than in type 2 ( $P = 0.00$ ), type 3 ( $P = 0.00$ ) and type 4 ( $P = 0.02$ ). Also, the internal angle in type 3 was smaller than that in type 4 ( $P = 0.04$ ).

Assessment of the scattering of the internal angle data showed that the scattering range of some types was different and there was no overlap. For example, type 1 did not overlap with types 2, 3, and 5 in this diagram. Therefore,

it was necessary to compare the types with each other in terms of angle.



**Figure 4.** Scatter diagram of different types regarding the mean bone with

The internal angle of premolars was  $23.2 \pm 0.87$  degrees in type 1,  $17.8 \pm 0.68$  degrees in type 2,  $14.1 \pm 4.2$  degrees in type 3,  $20 \pm 1.4$  degrees in type 4, and  $15.9 \pm 2.12$  degrees in type 5.

Comparison of types by angle showed that type 1 had little overlap with type 4 only; thus, if the measured angle is in the range of 21 to 24 degrees, the type of relationship can be predicted with good accuracy (type 1 with high probability and less likely type 4). The lowest accuracy was related to type 5 because its information was small compared with the statistical population and the data were scattered (it included a range of 11 to 20 degrees, which overlapped with the other 3 types).

## Discussion

The aim of this study was to assess the relationship of the maxillary premolars with the sinus floor and to find the mean width of the alveolar bone at the site of premolars and the mean internal angle between premolars and the alveolar bone and related factors in an Iranian

population. The obtained information can serve as a useful guide for implant placement at the site of maxillary premolars.

According to the results of this study, the mean width of alveolar bone at the site of premolars was not significantly different ( $9.9 \pm 1.4$  mm at the site of first premolars and  $9.8 \pm 1.1$  mm at the site of second premolars). Also, the mean internal angle was  $19.6 \pm 6.3$  degrees in first premolars and  $18.2 \pm 6.1$  degrees in second premolars, and this difference was not significant. The vertical relationship of the apex of premolars with the sinus floor was classified into five types, and the results showed that in both the first and second premolars, the frequency of type 2 was higher than other types. Comparison of alveolar bone width and internal angle among the 5 types showed that bone width did not differ significantly between types ( $P = 0.63$ ) while the internal angle was greater in type 1 than types 2, 3 and 4. In other words, we cannot predict the bone width at the crest based on the type of relationship of the tooth with the sinus floor; while, it seems that the closer the root to the sinus floor, the more it is in line with the alveolar bone level and the smaller the angle between the tooth and the ridge would be. Therefore, when the relationship between the tooth and the sinus floor is type 1 on two-dimensional radiographs, more care should be taken in surgical and implant treatments.

The results of this study on distributions of different types are close to the results of Nishihara et al (2). While in our study, type 2 had the highest frequency in both the first and second premolars, Nishihara et al. showed the highest frequency of type 2 only in second premolars, however the frequency of different types was not significantly different between males and females and in the right or left sides. This finding was consistent with the results of the present study. Regarding the mean width of the alveolar bone in the first and second premolars, the results of the present study (9.9 and 9.8 mm, respectively) seems not significantly different from those of Nishihara et al, (9.5 mm and 10 mm) and this shows that the risks of implant placement are equal at the sites

of first and second premolars.

Also Kwak et al. (13) in their study on a Korean population reported that type 1 root-to-sinus connection had the highest frequency as in our study. However, the mean bone width in the first and second premolars of the maxilla was 11.15 and 11.06 mm, respectively; which is more than the average bone width in our study. Racial and methodological differences are almost the reasons for the variations in the results of the two studies.

Many studies have investigated the relationship between the posterior teeth of the maxilla and the maxillary sinus floor, and in some of them, the classifications are different from each other and from our study.

For instance, in a study by Shokri et al. (14) the vertical relationship between the maxillary sinus floor and the roots of the maxillary posterior teeth was classified into 4 types instead of 5, and as in our study, type 0 (the maxillary sinus floor is located above the root apex) was the most common. Also in the study by Oishi et al. (15) the vertical relationship between the maxillary sinus floor and the roots of the maxillary posterior teeth was classified into 4 types and type 1 (the maxillary sinus floor is located above the root tip) was most frequently observed for the root of the maxillary canine and the first and second premolars in sagittal sections.

The classification of the relationship of tooth apices and the maxillary sinus floor in the study by Fuentes et al. (16) is slightly different from that in the present study. They classified 4 types and reported the lowest frequency for type 1 (root within the sinus) in first premolars and type 4 (root without sinus connection) in second premolars. Similar to our study, type 3 which is the condition where the sinus floor is seen above the root apex had the highest frequency. Also, similar to the present study, the prevalence of different types was not significantly different in different age groups, but contrary to our study, types 3 and 4 were more common in males than females. It seems that racial differences can affect the role of gender in the relationship between root apex

and sinus floor, because we did not find any difference between the two sexes in this regard. In Tian et al. (17) and Gu et al. (18) study, a simpler classification was used for the relationship between the tooth root and the sinus floor. They classified this relationship into three groups (IS: root within the sinus, CO: root in contact with the sinus, OS: root below the sinus). In their study, the root of most premolars had no contact with the sinus floor which is consistent with the results of our study but they showed that age had a significant effect on the relationship of the maxillary posterior roots and the maxillary sinus floor, and this distance increased with age. Gu et al. (18) also found no difference between males and females, which is similar to our study. In our study, we did not find any difference between age groups regarding the distance or relationship between teeth and sinuses. Racial differences may be one of the reasons for the differences in the results of the two studies on age groups. Absence of antagonistic teeth leads to over-eruption of the opposing teeth. Also, attrition usually occurs with age, and this can also lead to over-eruption and distancing of the root apex from the sinus floor. In our study, we excluded the patients that did not have the opposing teeth.

In 2020, Kaushik et al. (19) also used the same system and obtained a similar frequency. However, unlike our study and the studies by Shokri et al. (14) and Fuentes et al. (16) the distance between the roots and the sinus floor was shorter in males than in females, which can be related to racial differences.

There have been studies (20,21) that only examined the average distance between the roots of the posterior teeth to the maxillary sinus floor, and the type of communication has not been classified in the same way as the current study. Kilic et al (20) reported no significant difference between male and female however Jang et al (21) reported greater distances in male patients. Even in different skeletal classes, there was no significant difference between sexes and age groups in one study (22). Therefore, the role of race and

ethnicity in growth and skeletal patterns is again taken into consideration.

Based on our search in the databases, very few studies in the last 10 years have dealt with the subject of the internal angle in the maxilla. In the present study, the mean internal angle was 19.6 and 18.2 degrees for the first and second premolars, respectively. The reported value for the second premolars was close to that reported by Nishihara et al (18.1 degrees). (2) However, there was a difference in values for first premolars (25.5 degrees in their study. The average internal angles in the Dos santos et al. (23) study for the first and second premolar teeth, were 12.6 and 10.9 degrees, respectively, while López-Jarana et al. (24) reported an average of 13.93 degrees for the internal angle of both premolar teeth.

It seems that may be the difference in ethnicity can cause a difference in the shape and correspondingly the angle of the teeth in the jaw. Therefore, based on the results of the current study regarding both the first and second premolars, it is necessary to be careful about the angle of implant placement to prevent perforation of the buccal plate during implant placement.

To perform various dental procedures on maxillary premolars, it is necessary to know the inclination of the alveolar bone and the position of the maxillary sinus floor. Also, knowing the mean width of the alveolar bone at the site of premolars and also the mean internal angle between premolars and the alveolar bone and the frequency of various types of the relationship between the tooth root and the maxillary sinus floor can affect the success of implant placement at the site of maxillary premolars.

## Conclusion

The present study evaluated the relationship of maxillary premolars relative to the maxillary sinus floor and alveolar bone in an Iranian population. According to the results of this study, the most common type of relationship between the first and second premolar teeth with the sinus floor is type 2, and the internal angle for the first premolar teeth is greater than

that of the second premolar. Also, there is no difference between the two sexes and age groups in the type of connection between the teeth and the sinus floor. Knowledge of the anatomical relationship between the maxillary sinus floor and the maxillary posterior teeth root tips is important for the preoperative treatment planning of maxillary posterior teeth. In absence of 3D imaging, the results of the present study may be useful for dental treatments at the maxillary premolar region.

## References

1. Yoshimine SI, Nishihara K, Nozoe E, Yoshimine M, Nakamura N. Topographic analysis of maxillary premolars and molars and maxillary sinus using cone beam computed tomography. *Implant dent*. 2012 Dec 1; 21(6):528-35.
2. Nishihara K, Yoshimine SI, Goto T, Ishihata K, Kume KI, Yoshimura T et al. Topographic analysis of the maxillary premolars relative to the maxillary sinus and the alveolar bone using cone beam computed tomography. *Oral surg oral med oral pathol oral radiol*. 2017 May 1; 123(5):606-12.
3. Altaweel AA, Sowairi SMS, Sapri AMS, Saeedi SA, Alamri AH, Alnobi AA et al. Assessment of the Relationship between Maxillary Posterior Teeth and Maxillary Sinus Using Cone-Beam Computed Tomography. *Int J den*. 2022 Jul 5; 1-7.
4. Ragab MH, Abdalla AY, Sharaan ME. Location of the Maxillary Posterior Tooth Apices to the Sinus Floor in an Egyptian Subpopulation Using Cone-beam Computed Tomography. *IEJ*. 2022;17(1):7-12.
5. Sawicka M, Bedini R, Pecci R, Pameijer CH, Kmiec Z. The application of X-ray microtomography for the assessment of root resorption caused by the orthodontic treatment of premolars. *Ann Ist Super Sanita*. 2012;48:71-4.
6. Fuhrmann R, Bückner A, Diedrich P. Radiological assessment of artificial bone defects in the floor of the maxillary sinus. *Dentomaxillofac Radiol*. 1997 Mar;26(2):112-6.
7. Garcia B, Penarrocha M, Martí E, Martínez JM, Gay-Escoda C. Periapical surgery in maxillary premolars and molars: analysis in terms of the distance between the lesion and the maxillary sinus. *J Oral Maxillofac Surg*. 2008 Jun 1;66(6):1212-7.
8. Neugebauer J, Ritter L, Mischkowski RA, Dreiseidler T, Scherer P, Ketterle M et al. Evaluation

of maxillary sinus anatomy by cone-beam CT prior to sinus floor elevation. *Int J Oral Maxillofac Implants*. 2010 Apr 1;25(2).

9. Nowzari H, Molayem S, Chiu CH, Rich SK. Cone beam computed tomographic measurement of maxillary central incisors to determine prevalence of facial alveolar bone width  $\geq 2$  mm. *Clin Implant Dent Relat Res*. 2012 Aug;14(4):595-602.

10. Hashimoto K, Kawashima S, Araki M, Iwai K, Sawada K, Akiyama Y. Comparison of image performance between cone-beam computed tomography for dental use and four-row multidetector helical CT. *J Oral Sci*. 2006;48(1):27-34.

11. Hashimoto K, Arai Y, Iwai K, Araki M, Kawashima S, Terakado M. A comparison of a new limited cone beam computed tomography machine for dental use with a multidetector row helical CT machine. *Oral Surg Oral Med Oral Pathol Oral Radiol Endod*. 2003 Mar 1;95(3):371-7.

12. Loubele M, Van Assche N, Carpentier K, Maes F, Jacobs R, van Steenberghe D et al. Comparative localized linear accuracy of small-field cone-beam CT and multislice CT for alveolar bone measurements. *Oral Surg Oral Med Oral Pathol Oral Radiol Endod*. 2008 Apr 1;105(4):512-8.

13. Kwak HH, Park HD, Yoon HR, Kang MK, Koh KS, Kim HJ. Topographic anatomy of the inferior wall of the maxillary sinus in Koreans. *Int J Oral Maxillofac Surg*. 2004 Jun 1; 33(4):382-8.

14. Shokri A, Lari S, Yousef F, Hashemi L. Assessment of the relationship between the maxillary sinus floor and maxillary posterior teeth roots using cone beam computed tomography. *J Contemp Dent Pract*. 2014; 15(5):618-22.

15. Oishi S, Ishida Y, Matsumura T, Kita S, Sakaguchi-Kuma T, Imamura T et al. A cone-beam computed tomographic assessment of the proximity of the maxillary canine and posterior teeth to the maxillary sinus floor: Lessons from 4778 roots. *Am J Orthod Dentofacial Orthop*. 2020 Jun;157(6):792-802.

16. Fuentes R, Arellano-Villalón M, Soto-Faúndez N, Arias A, Montiel I, Borie E, et al. Assessment of Maxillary Premolar Region in Relation to Maxillary

Sinus Floor and Buccal Bone Plate: A Cone Beam Computed Tomography Study. *Int J Morphol*. 2019 Jul 1; 37(3).

17. Tian XM, Qian L, Xin XZ, Wei B, Gong Y. An analysis of the proximity of maxillary posterior teeth to the maxillary sinus using cone-beam computed tomography. *J Endod*. 2016 Mar 1; 42(3):371-7.

18. Gu Y, Sun C, Wu D, Zhu Q, Leng D, Zhou Y. Evaluation of the relationship between maxillary posterior teeth and the maxillary sinus floor using cone-beam computed tomography. *BMC oral health*. 2018 Dec; 18(1):1-7.

19. Kaushik M, Kaushik P, Mehra N, Sharma R, Soujanya E, Kumar U. Anatomical relationship between roots of maxillary posterior teeth and maxillary sinus using cone-beam computed tomography. *Endodontology*. 2020 Jul 1;32(3):124.

20. Kilic C, Kamburoglu K, Yuksel SP, Ozen T. An assessment of the relationship between the maxillary sinus floor and the maxillary posterior teeth root tips using dental cone-beam computerized tomography. *Eur J Dent*. 2010 Oct; 4(04):462-7.

21. Jang JK, Kwak SW, Ha JH, Kim HC. Anatomical relationship of maxillary posterior teeth with the sinus floor and buccal cortex. *J Oral Rehabil*. 2017 Aug; 44(8):617-25.

22. Shrestha B, Shrestha R, Lu H, Mai Z, Chen N, Chen Z et al. Relationship of the maxillary posterior teeth and maxillary sinus floor in different skeletal growth patterns: A cone-beam computed tomographic study of 1600 roots. *Imaging Sci Dent* 2022; 52: 19-25.

23. Dos Santos JG, Durão AP, de Campos Felino AC, de Faria RM. Analysis of the Buccal Bone Plate, Root Inclination and Alveolar Bone Dimensions in the Jawbone. A Descriptive Study Using Cone-Beam Computed Tomography. *J Oral Maxillofac Res*. 2019 Apr; 10(2).

24. P. López-Jarana, C. M. Díaz-Castro, A. Falcão, C. Falcão, J. V. Ríos-Santos, M. Herrero-Climent. Thickness of the buccal bone wall and root angulation in the maxilla and mandible: an approach to cone beam computed tomography. *BMC Oral Health*. 2018 Nov; 18:1-9.