

Revascularization Treatment of Immature Permanent Tooth with Necrotic Pulp: A Case Report

B. Seraj ¹, M. Sohrabi ^{2✉}, M. Shafizadeh ².

¹ Associate Professor, Dental Research Center, Dentistry Research Institute, Tehran University of Medical Sciences, Tehran, Iran AND Department of Pediatric Dentistry, School of Dentistry, Tehran University of Medical Sciences, Tehran, Iran

² Postgraduate Student, Department of Pediatric Dentistry, School of Dentistry, Tehran University of Medical Sciences, Tehran, Iran

Abstract

Introduction: Revascularization is the newest treatment proposed for an immature permanent tooth with necrotic pulp. Revascularization is defined as a treatment process with a biological base which is aimed at replacing the lost structures and the continued development of roots.

Case presentation: Patient was an eight-year-old child with the history of trauma to the maxillary anterior region. After clinical and radiographic evaluations, tooth #9 was diagnosed with the pulp necrosis, and revascularization was carried out according to Banch and Trope principles.

Conclusion: The clinical and radiographic evaluation after treatment revealed no signs and symptoms and root development was in progress which was an indication of successful treatment. It seems that, in the case of proper selection of the patient, this method can be an appropriate replacement for apexification in immature teeth with pulp necrosis.

Key Words: Necrosis, Dental Pulp, Regeneration, Apexification

✉ Corresponding author:
M. Sohrabi, Postgraduate
Student, Department of
Pediatric Dentistry, School of
Dentistry, Tehran University
of Medical Sciences, Tehran,
Iran

Monasohraby@yahoo.com

Received: 24 Sep 2017

Accepted: 9 Jan 2018

➤ Cite this article as: Seraj B, Sohrabi M, Shafizadeh M. Revascularization Treatment of Immature Permanent Tooth with Necrotic Pulp: A Case Report. J Islam Dent Assoc Iran. 2018; 30(1):39-43. DOI: 10.30699/JIsdreir.30.1.39

Introduction

Immature teeth have thin dentinal walls and open apices. Thus, root canal treatment in immature teeth is a difficult procedure, in particular, apical sealing is very challenging [1,2]. Conventional treatments for these cases include apexification with calcium hydroxide and Mineral Trioxide Aggregate (MTA). Although sealing the apex could be achieved via apexification, it often would not increase the length and the thickness of root canal wall, and as a result, the tooth is susceptible to cervical fractures [3].

Revascularization has been proposed as the newest

treatment for immature necrotic teeth and is based on tissue engineering. Tissue engineering is the basis of other therapeutic approaches including guided tissue regeneration, guided bone regeneration, and distraction osteogenesis. Stem cells, scaffolds, and growth factors are essential elements of tissue engineering [4]. The minimum expectations of revascularization treatment is the absence of undesirable signs and symptoms, however, the ultimate goals are the full regeneration of pulp complex and development of the root to its most ideal state [5, 6].

Case presentation

An eight-year-old girl was referred to the Department of Pediatric Dentistry of Dental School of Dentistry, Tehran University of Medical Sciences for treatment of left maxillary central incisor. The chief complaint of the patient was a dental abscess which according to her parents had a three-month history. Clinical examination of the patient showed an uncomplicated crown fracture of #9 tooth without receiving any treatment during this period. Percussion test was normal, the score of tooth mobility was grade I, and the results of electric pulp test (EPT) and cold stimuli were negative. The fistula was observed in the buccal vestibule. Periapical radiography from the anterior maxilla showed immature teeth with open apex and thin dentinal walls in both maxillary incisors. A radiolucent area was also observed on apical region of tooth #9 (Figure 1). Clinical and radiographic evaluation pointed to pulp necrosis with a chronic apical abscess. Treatment plans of apexification and revascularization were explained to the patient's parents, and revascularization was chosen by them for treatment. The informed consent was obtained from patient's parents.

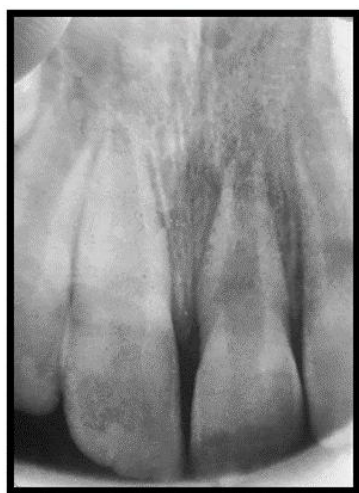

Figure 1. The initial periapical X-ray showing immature central incisor with the open apex and a radiolucent area in the apical region

First visit

After applying local anesthesia (2% lidocaine with 1:100000 epinephrine), the tooth isolation was obtained by rubber dam and access cavity was

prepared. The exudates were drained from the canal after access preparation. Working length was 19.8 mm which was determined radiographically. The root canal was irrigated gently with 20 ml of 1.5% sodium hypochlorite for 5 minutes followed by 20 ml saline solution for 5 minutes. Then the canal was dried with paper points. The triple antibiotic paste was prepared with mixing equal proportions of Metronidazole (Tab 250 mg, Parsdarou, Iran), ciprofloxacin (Tab 500 mg, Alborzdarou, Iran), Clindamycin (Capsule 150 mg, Soha, Iran). This antibiotic mixture was placed into the canal using a lentulo. Finally, the canal was sealed with a resin-modified glass ionomer (Fuji II LC Restorative GI, Japan).

Second visit

After approximately three weeks, the patient returned for examination. First, the tooth was evaluated for the presence of signs and symptoms, then based on the suitable conditions of the tooth, treatment was continued. Mepivacaine 3% (without a vasoconstrictor) was administered to anesthetize the tooth, followed by isolating it with a rubber dam. After preparing access cavity, the antibiotic paste was extracted from the canal using normal saline. Next, the canal was dried with the paper points. Intracanal bleeding was induced through over instrumentation by an endodontic file (#25). When bleeding was reached to CEJ region, MTA (white OrthoMTA; BioMTA, Korea) with 4 mm thickness was placed, then a resin-modified glass ionomer (Fuji II LC Restorative GI, Japan) was used to seal the area (Figure 2).

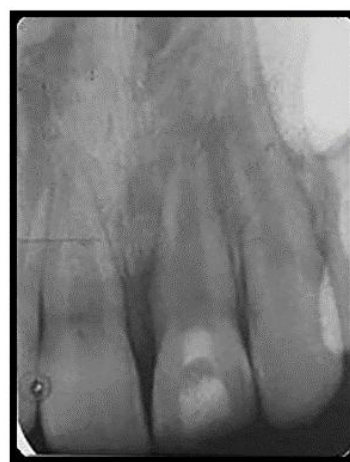

Figure 2. Postoperative radiograph

Follow-up

Follow-up visits were set at 1, 3, 6, 12, 24, and 36 months after the second appointment. Radiographic analyses and clinical assessment including gingival appearance, percussion, vitality test, mobility, functionality, and discoloration, were carried out in each appointment (Figure 3). The tooth was

functional in all sessions, and no adverse signs or symptoms were observed (Figure 4). Radiographic assessment showed that the tooth apex was closed 24 months after treatment and displayed similar size to the right central incisor (Figure 3e). EPT and cold tests were negative for tooth #9, while they were positive for tooth #8.

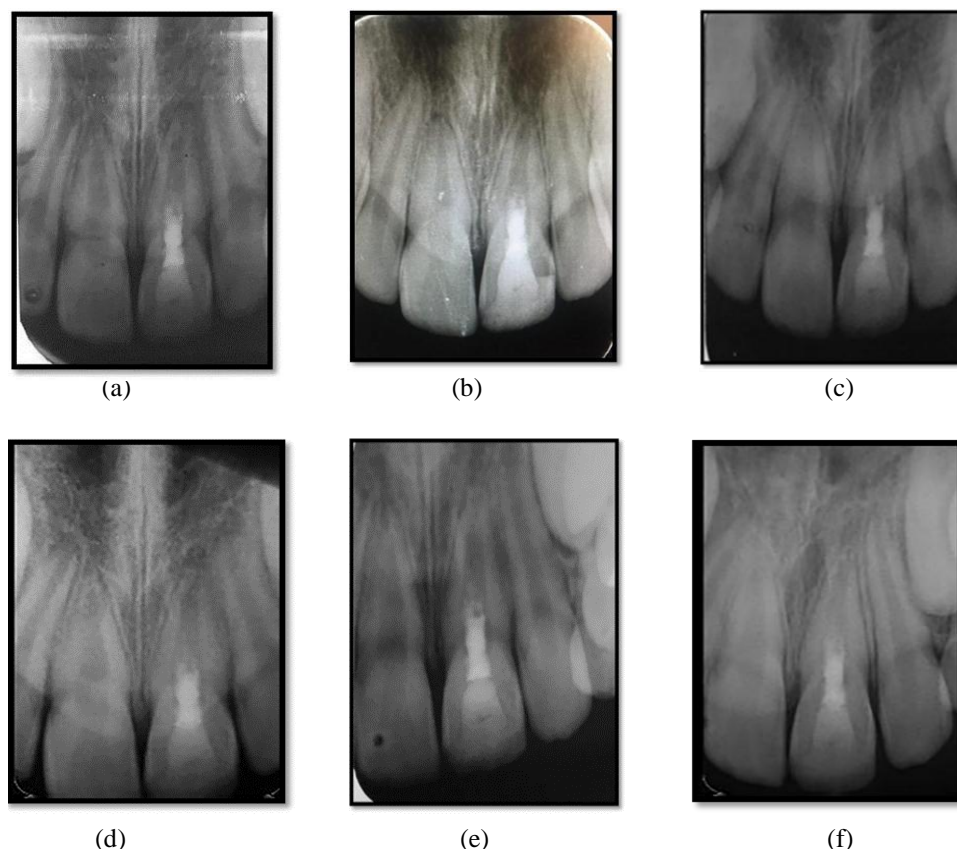


Figure 3. Follow-up radiographs: a, b, and c were taken one, 3, and 6 months after revitalization, respectively; (d) the periapical radiolucency has resolved 12 months after revitalization; (e) 24 months after revitalization, Apex closure was observed; (f) three years after the start of treatment

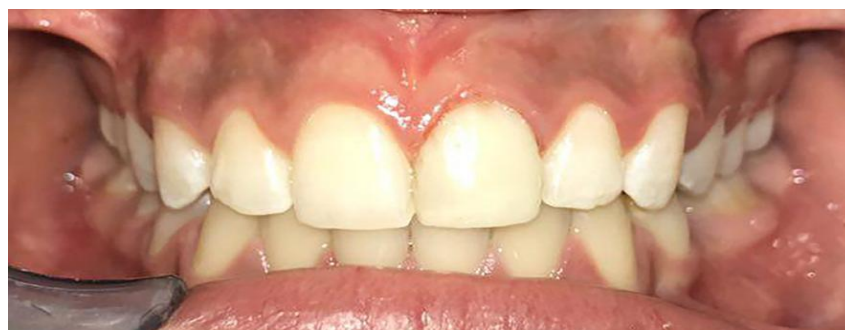

Figure 4. The follow-up photograph three years after revitalization

Discussion

The concept of endodontic regenerative treatment was first introduced by Nygaard-Ostby [5]. The Banch and Trope's protocol was later introduced for regeneration [1, 5].

This case report illustrates the successful revascularization treatment of left maxillary central incisor which had a chronic apical abscess, during three-year follow-ups. Among the possible treatment protocols for this patient, revascularization was carried out due to parents' preference. Although apexification may cause complete closure of apex, it does not promote root development. Moreover, long-term use of calcium hydroxide in apexification is followed by a potential increase of root fracture [1, 3].

Geisler [6] has expressed three objectives of successful regeneration. The first goal is the absence of adverse signs and symptoms and radiographic evidence of periapical healing [5, 6]. Regarding the present case, during the follow-up sessions, no unfavorable signs and symptoms were observed after three weeks, and periapical radiolucency reduced after twelve months (Figure 3d). The second goal of the regeneration is increasing the root length and thickening the root canal walls [5, 6]. Tracking the treatment outcomes in regular follow-ups revealed that apex closure was attained two years after starting the treatment (Figure 3e). It has been shown that the thickness of root canal walls would be increased more by using triple antibiotic paste compared to calcium hydroxide, especially when it is placed beyond the coronal half of the tooth [7]. The third purpose of regeneration, which is the indication of the highest level of success, is the positive response to vitality tests [5, 6]. In the present patient, response to EPT and thermal stimuli in follow-up sessions was negative.

For a successful regeneration, case selection and treatment process are important. Root development process in revascularized immature necrotic teeth depends on the survival of Hertwig epithelial root sheath in the patients with periodontitis/apical abscess. Epithelial sheath might be involved in modulating the differentiation of PDL stem cells [8].

Root canal cleaning provides an appropriate environment for pulpal and periapical cells to get

involved in tissue repair and regeneration after trauma [3]. There are doubts regarding the recent protocol of root canal disinfection during regeneration process including whether minimum debridement of root canal walls would be able to eliminate the most of canal bacteria in clinical conditions. In a case report by Lin et al. [9], they performed a histological and histobacteriological analyses of a tooth with the unsuccessful regeneration outcomes. They have concluded that the treatment failure was due to the presence of bacteria in the apical area of the root canal and formation of biofilm on the root canal walls and their penetration into dentinal tubules. Therefore, further analyses are required to determine the proper methods of root canal disinfection and whether minimum debridement or lack of debridement is required [9].

Tooth discoloration subsequent to the treatment with this technique could be due to the use of triple antibiotic paste or application of MTA at the end of treatment [1]. Tooth discoloration occurred in the present case and bleaching was suggested for the further treatment. To prevent tooth discoloration in subsequent patients, minocycline could be replaced by clindamycin or eliminated from the antibiotic paste composition [5]. Also, propylene glycol can be added to MTA to reduce its discoloration effects or MTA might be replaced with biodentine [1].

The present treatment protocol for an immature permanent tooth with necrotic pulp needs more investigations in order to improve the success rate of the treatment. Inquiries about the mechanical and chemical aspect of canal disinfection including different decontaminating materials and filling methods seem necessary.

Conclusion

The present case report illustrates a three-year follow-up of revascularization of a tooth using triple antibiotic paste as the disinfectant. Treatment was considered successful since all unfavorable signs and symptoms have been eliminated and root developed satisfactorily.

References

1. Silva MHC, Campos CN, Coelho MS. Revascularization of an immature tooth with apical

- periodontitis using calcium hydroxide: a 3-year follow-up. *Open Dent J.* 2015 Dec;31(9):482-5.
2. Hargreaves KM, Diogenes A, Teixeira FB. Paradigm lost: a perspective on the design and interpretation of regenerative endodontic research. *J Endod.* 2014 Apr;40(4 Suppl):S65-9.
3. Chen MY, Chen KL, Chen CA, Tayebaty F, Rosenberg PA, Lin LM. Responses of immature permanent teeth with infected necrotic pulp tissue and apical periodontitis/abscess to revascularization procedures. *Int Endod J.* 2012 Mar;45(3):294-305.
4. Hargreaves KM, Berman LH, Rotstein I. Cohen's pathways of the pulp. Elsevier Health Sciences, 2016; Chapter 10:447-454.
5. Dean JA. McDonald and Avery's Dentistry for the Child and Adolescent. Elsevier Health Sciences, 2016;Chapter 27:576-579.
6. Geisler TM. Clinical considerations for regenerative endodontic procedures. *Dent Clin North Am.* 2012 Jul;56(3):603-26.
7. Bose R, Nummikoski P, Hargreaves K. A retrospective evaluation of radiographic outcomes in immature teeth with necrotic root canal systems treated with regenerative endodontic procedures. *J Endod.* 2009 Oct;35(10):1343-9.
8. Saeki K, Fujita Y, Shiono Y, Morimoto Y, Maki K. Pulp revascularization in immature permanent tooth with apical periodontitis using mineral trioxide aggregate. *Case Rep Med.* 2014;2014: 564908.
9. Lin LM, Shimizu E, Gibbs JL, Loghin S, Ricucci D. Histologic and histobacteriologic observations of failed revascularization/ revascularization therapy: a case report. *J Endod.* 2014 Feb;40(2):291-5.