

OCT-4 Is a Good Predictive Biomarker for Local Recurrence in Head and Neck Basal Cell Carcinoma

F. Baghai Naini ¹, K. Kamyab Hesari ², N. Mahdavi ³, S. Derakhshan ³✉.

¹ Associate Professor, Dental Research Center, Dentistry Research Institute, Tehran University of Medical Sciences, AND Department of Oral and Maxillofacial Pathology, School of Dentistry, Tehran University of Medical Sciences, Tehran, Iran

² Associate Professor, Department of Dermatopathology, Razi Hospital, Tehran University of Medical Sciences, Tehran, Iran

³ Assistant Professor, Department of Oral and Maxillofacial Pathology, School of Dentistry, Tehran University of Medical Sciences, Tehran, Iran

Abstract

Background and Aim: Basal cell carcinoma (BCC) is considered to be the most common malignancy in humans and occurs primarily in the skin especially in the head and neck region. Considering the high recurrence rate of the tumor, finding a marker for prediction of recurrence is very important. Cancer stem cells are a small subpopulation in the tumors that are related to tumorigenesis and recurrence and OCT4 is a known stem cell marker. The present study was designed to explore the relation between expression of OCT4 in the head and neck basal cell carcinoma and recurrence of the tumor.

Materials and Methods: This study was performed on 84 patients with head and neck BCC who were followed up for 24 months. Immunohistochemical expression of OCT4 was assessed in paraffin embedded blocks.

Results: Positive expression of OCT4 was significantly associated with the recurrence rate ($P < 0.001$).

Conclusion: We conclude that the expression of OCT4 can serve as a predictive marker for tumor recurrence in the head and neck basal cell carcinoma.

Key Words: Carcinoma, Carcinoma, Basal Cell, Neoplastic Stem Cells, Recurrence

✉ Corresponding author:
S. Derakhshan, Assistant
Professor, Department of Oral
and Maxillofacial Pathology,
School of Dentistry, Tehran
University of Medical
Sciences, Tehran, Iran

samderakhshan.den@gmail.com

Received: 1 Jan 2017

Accepted: 21 Mar 2017

➤ **Cite this article as:** Baghai Naini F, Kamyab Hesari K, Mahdavi N, Derakhshan S. OCT-4 Is a Good Predictive Biomarker for Local Recurrence in Head and Neck Basal Cell Carcinoma. J Islam Dent Assoc Iran. 2017; 29(2):58-63. DOI: 10.30699/jidai.29.2.58

Introduction

Basal cell carcinoma (BCC) is the most common type of cancer which accounts for nearly 25% of all cancers in the human body and for almost 75% of skin malignancies [1]. The head and neck region is the most common skin site for development of BCC and up to 85% of BCCs develop in the head and neck region [1-4]. The incidence of skin cancer is exponentially increasing worldwide, with some estimates reporting up to 10 % annual increase in incidence [5]. As a fact, recurrent BCC is more difficult to cure than primary tumors [6], with overall 5-year re-recurrence rates reported as

high as 15.4% [7]. BCC can be treated using a variety of methods including electrodesiccation, curettage, cryotherapy, Mohs micrographic surgery, radiation therapy, topical immunomodulators, photodynamic therapy and surgical excision [8]. Surgery is the principal form of treatment used [9]. The strongest predictors for tumor recurrence include positive excision margins and high-risk histological types [10].

Cancer stem cells (CSCs) are a small population of cells within tumors with the potential for self-renewal that can eventually lead to tumorigenesis [11]. Growing evidence suggests that these cells

are associated with recurrence and resistance to radiation and chemotherapeutic treatments [12]. OCT4, also known as OCT3, belongs to the POU (Pit-Oct-Unc) transcription factor family [13]. The POU family of transcription factors can induce the expression of their target genes through binding to the octameric sequence motif with an AGTCAAAT consensus sequence [14]. Many cancers express OCT4 and it has been shown that its expression is of great importance for cancer cell survival [15]. OCT4 constitutes a part of an important gene regulatory network that is essential for embryogenesis and retention of pluripotency and self-renewal in embryonic stem cells [16]. OCT4 is a known marker of CSCs which induces tumorigenesis as well as self-renewal ability. Some studies reported small number of OCT4 immunopositive cells scattered among the basal cells of epidermis and hair follicle bulge in the human scalp [17, 18].

To the best of our knowledge, this study is the first to investigate the association between OCT-4 and local recurrence in patients with head and neck basal cell carcinoma.

Materials and Methods

Sampling:

The protocol for this study was approved by the Research and Ethics Committee of Tehran University of Medical Sciences. This study was performed on 84 patients with head and neck basal cell carcinoma who were referred to Razi Hospital, Tehran, Iran, from March 1 to September 30, 2012. Only primary tumors without any history of other skin cancers or radiotherapy were accepted. Six cases were excluded because of unsuccessful follow up and 78 cases were followed up for 24 months.

Immunohistochemistry:

Immunohistochemical analysis of OCT4 was performed on 4 µm sections. The Envision Plus detection system (Dako, Carpinteria, CA, Denmark) was used for immunostaining. The sections were deparaffinized in xylene and microwaved in 10 mmol/L citrate buffer (pH 6.0) to unmask the epitopes. Endogenous peroxidase activity was blocked by incubation with 0.03% hydrogen peroxide in methanol for 5 minutes. For the detection of OCT4, the sections were incubated

with the liquid mouse Monoclonal OCT4 antibody (Novocastra, Leica Biosystems, London, UK) by heat induced epitope retrieval technique in citrate-based buffer containing surfactant PH6 in 1:100 concentrations for 30 minutes at room temperature. The slides were washed in TBS for 10 minutes, counterstained with hematoxylin, dehydrated and mounted. Known OCT4 positive seminoma was used as positive control. The negative control was obtained by omitting the primary antibody. Brown nuclear staining was considered positive. Both intensity and percentage of immunostained tumor cells were taken into consideration [15]. The extent of positivity was scored as 0 when no positive cells were observed; 1 when the percentage of positive cells was < 10%; 2 when it was 10%-50%, and 3 when it was > 50%. The intensity was scored as 0 when no positive cells were identified; 1, weak; 2, moderate; and 3, strong staining. The final immunostaining score was determined by the multiplication of the two above-mentioned scores: Score 0-2 as weak or final score 0; score 3-4 as moderate or final score 1 and score 6 and 9 as strong or final score 2 [15].

Statistical analysis:

Data were analyzed using SPSS software version 18.0 (SPSS Inc., IL, USA) and $P < 0.05$ was considered statistically significant. For comparison of intensity, percentage and scores in the two groups (with or without recurrence), the Mann-Whitney test was used. For comparison of gender, site of tumor and tumor type with recurrence, the Fisher's Exact test was used. Independent t-test was used for the comparison of age in the two groups.

Results

The present study was performed on 84 cases of head and neck BCC. Seven cases (9%) showed recurrence (Table 1) and 78 cases were followed up for 24 months; 6 cases were failed to follow up. Statistical analysis to evaluate the correlation of recurrence with OCT4 expression and clinicopathologic features was only performed on 78 cases who were followed up.

OCT4 expression by the tumor cells:

Regarding the intensity of OCT4 staining, 25 cases (30%) were negative for OCT4, 49 cases (58%)

Table 1. Correlation of recurrence with OCT4 expression and clinicopathologic features

		Recurrence (%)		P value
		Yes	No	
Gender	Male	4(57.1%)	48(67.6%)	0.68
	Female	3(42.9%)	23(32.4%)	
Location	scalp	4(57.1%)	22(31.0%)	
	Face or neck	3(42.9%)	49(69.0%)	
	solid or nodular	6(85.7%)	54(76.1%)	
Histologic subtype of tumor	Infiltrating	1(14.3%)	6(8.5%)	0.49
	Superficial	0(0.0%)	11(15.5%)	
	Score 0	0(0.0%)	24(33.8%)	
Intensity of reaction	Score 1	0(0.0%)	44(62.0%)	0.000*
	Score 2	7(100.0%)	3(4.2%)	
	Score 3	0(0.0%)	0(0.0%)	
Percentage of positive cells (%)	Score 0	0(0.0%)	24(33.8%)	0.000*
	Score 1	0(0.0%)	36(50.7%)	
	Score 2	5(71.4%)	11(15.5%)	
	Score 3	2(28.6%)	0(0.0%)	
Total score (intensity x percentage)	No or weak staining	0(0.0%)	70(98.6%)	0.000*
	Moderate staining	5(71.4%)	1(1.4%)	
	Severe staining	2(28.6%)	0(0.0%)	
Age (years)	Mean	62.57	63.20	0.903
	Median	61.00	63.00	
	Minimum	48.00	26.00	
	Maximum	88.00	91.00	
	Standard deviation	12.63	11.88	

*Statistically significant correlation

were weakly stained and 10 (12%) were moderately stained. None of the cases showed severe staining intensity (Figure 1). Regarding the number of immunopositive cells, 25 cases (30%) showed no staining, 39 cases (46%) were scored as 1 (< 10%), 18 cases (22%) were scored as 2 (10%-50%) and 2 cases (2%) were scored as 3 (>50%). Regarding the total score (intensity*percentage), 76 cases (90%) were classified as either negative or weakly positive for OCT4 immunostaining and scored as 0. Six cases (7%) were scored as 3 or 4 and classified as moderately positive (score 1). Two cases (3%) were scored as 6 or 9 and classified as strongly positive (Table 1).

OCT4 expression and recurrence:

All of seven patients with recurrence showed moderate intensity of staining for OCT4. In five cases (71%), number of the positive cells was scored as 2 and in two cases (29%), number of positive cells was scored as 3. Total score for five cases (71%) was 1 and two cases (29%) were scored as 2. Recurrence of the tumor was significantly correlated with the expression of OCT4 ($P < 0.001$; Table 1).

Clinicopathologic correlations:

Recurrence was not significantly correlated with age, sex, tumor location or histological subtype in seven patients with recurrence.

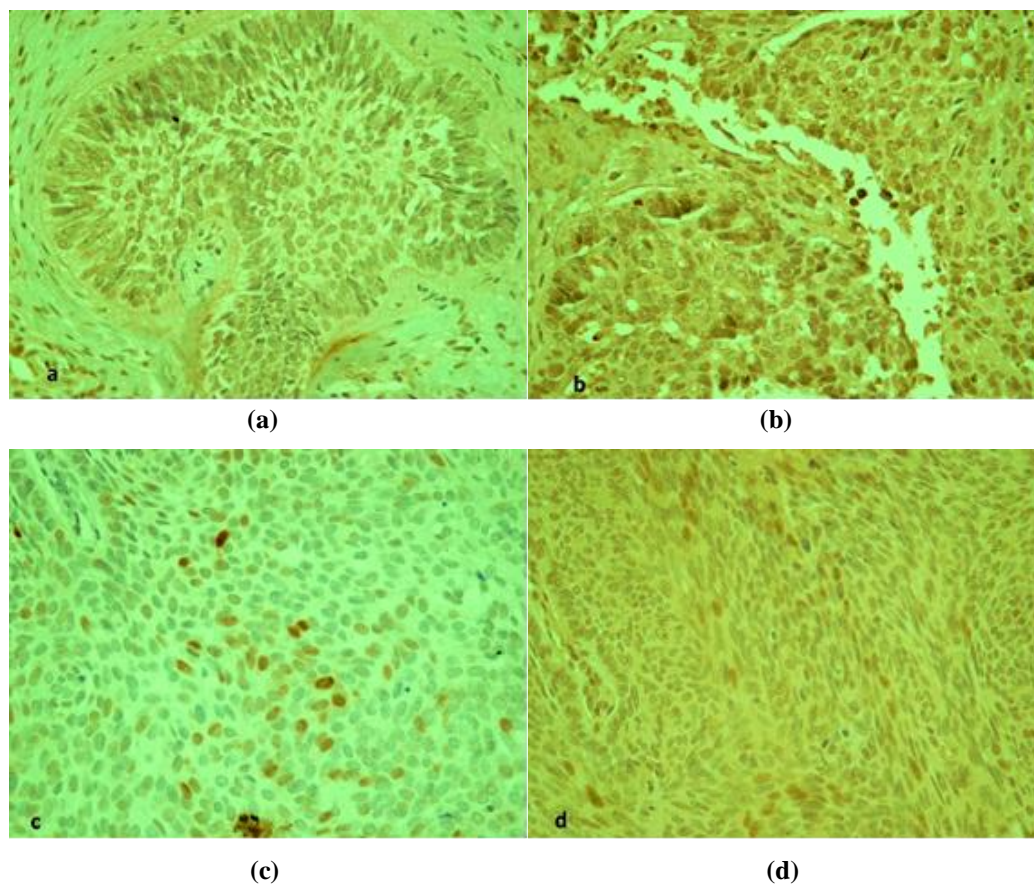


Figure 1. Nuclear immunoreactivity for OCT4 in BCC cells. (a) Weak staining in more than %50 of cells ($\times 400$). (b) Moderate intensity of staining in more than 50% of the tumor cells ($\times 400$). (c) Moderate intensity of staining in less than % 10 of the cells ($\times 400$). (d) Moderate intensity of staining in 10-50% of the tumor cells ($\times 400$).

Discussion

BCC is the most common skin malignancy. Although metastases are extremely rare, advanced local invasion may cause significant and sometimes severe morbidity [19]. The diagnosis of BCC is based on clinical findings and is confirmed by subsequent histopathologic evaluation. CSCs are small subpopulation of tumor cells responsible for tumorigenesis, recurrence and resistance to radiation and chemotherapeutic treatments [11, 12].

OCT4, as one of the most important transcription factors, plays a pivotal role in function of pluripotent stem cells and is expressed by CSCs [20]. OCT4 modulates a series

of signaling pathways, such as the Wnt/b-catenin, TGF- β and JAK/STAT3 signaling pathways [21, 22].

In this study, for the first time, we assessed the correlation of presence of OCT4 + cancer stem cells in BCC and tumor recurrence. The fact that 70% of the cases in our study showed immunopositivity for OCT4 demonstrates the presence of cancer stem cells in BCC. These stem cells form a small population usually counting for less than 1% of tumor cells in different tumor types; however, they play important roles in tumor recurrence [23]. Based on our results, total score as well as the intensity of OCT4 staining and percentage of positive cells were significantly

higher in recurrent BCCs; this indicates differences in tumor cells characteristics in BCCs with the tendency to recur. There is no documented study on assessment of BCC recurrence with or without any relation to stem cell markers. Considering the fact that treatment of recurrent cases is more difficult, finding a predictive marker of recurrence can lead to more effective removal of primary tumor and prevent further recurrence. It is important to preserve as much normal tissue as possible, thus optimizing the possibility of achieving good esthetic results with minimal intervention [24]. However, the type of treatment influences the recurrence rate. Treatment of BCC with Mohs micrographic surgery has the lowest recurrence rate [1]. The recurrence rate for tumors treated with Mohs micrographic surgery is approximately 1% at five years; whereas, standard surgical excision has approximately 5% recurrence rate at five years [1].

There is no general agreement regarding the appropriate follow up period for BCC in the literature. Some authors reported that follow-up longer than 3-4 years has limited benefit [25]; while others recommended a longer follow-up, stating that the actual risk for the occurrence of a second BCC or a recurrent BCC increases over time [26]. Since it has been reported that most local recurrences of BCC occur within the first two years after treatment [27], in the present study, we conducted a two-year follow up period. The results justify a longer follow up planning for patients with immunopositive reaction for OCT4; additional long-term studies are required for better understanding of the prognostic significance of these predictors.

Conclusion

Evidence from the present study suggests that the expression of OCT4 is a strong predictor for recurrence of BCC of the head and neck.

Acknowledgement

This study was supported by a grant from Dental Research Center, Tehran University of Medical Sciences (#93-01-69-24955).

References

1. Firnhaber JM. Diagnosis and treatment of basal cell and squamous cell carcinoma. *Am Fam Physician*. 2012 Jul 15;86(2):161-8.
2. Miller SJ. Biology of basal cell carcinoma (part I). *J Am Acad Dermatol*. 1991 Jan;24(1):1-13.
3. Tiftikcioglu YO, Karaaslan O, Aksoy HM, Aksoy B, Kocer U. Basal cell carcinoma in Turkey. *J Dermatol*. 2006 Feb;33(2):91-5.
4. Gudi V, Ormerod AD, Dawn G, Green C, MacKie RM, Douglas WS, et al. Management of basal cell carcinoma by surveyed dermatologists in Scotland. *Clin Exp Dermatol*. 2006 Sep;31(5):648-52.
5. Bath-Hextall F, Leonardi-Bee J, Smith C, Meal A, Hubbard R. Trends in incidence of skin basal cell carcinoma. Additional evidence from a UK primary care database study. *Int J Cancer*. 2007 Nov 1;121(9):2105-8.
6. Hamilton JR, Parvataneni R, Stuart SE, Chren MM. Rerecurrence 5 years after treatment of recurrent cutaneous basal cell and squamous cell carcinoma. *JAMA Dermatol*. 2013 May;149(5):616-618.
7. Silverman MK, Kopf AW, Grin CM, Bart RS, Levenstein MJ. Recurrence rates of treated basal cell carcinomas, Part 1: Overview. *J Dermatol Surg Oncol*. 1991 Sep;17(9):713-8.
8. Braun RP, Klumb F, Girard C, Bandon D, Salomon D, Skaria A, et al. Three-dimensional reconstruction of basal cell carcinomas. *Dermatol Surg*. 2005 May;31(5):562-6.
9. Farhi D, Dupin N, Palangié A, Carlotti A, Avril MF. Incomplete excision of basal cell carcinoma: rate and associated factors among 362 consecutive cases. *Dermatol Surg*. 2007 Oct;33(10):1207-14.
10. Kyrgidis A, Vahtsevanos K, Tzellos TG, Xirou P, Kitikidou K, Antoniadis K, et al. Clinical, histological and demographic predictors for recurrence and second primary tumors of head and neck basal cell carcinoma. A 1062 patient-cohort study from a tertiary cancer referral hospital. *Eur J Dermatol*. 2010 May-Jun;20(3):276-82.
11. Reya T, Morrison SJ, Clarke MF, Weissman IL. Stem cells cancer and cancer stem cells. *Nature*. 2001 Nov 1;414(6859):105-11.

12. Suresh R, Ali S, Ahmad A, Philip PA, Sarkar FH. The role of cancer stem cells in recurrent and drug-resistant lung cancer. *Adv Exp Med Biol.* 2016; 890:57-74.
13. Schöler HR, Ruppert S, Suzuki N, Chowdhury K, Gruss P. New type of POU domain in germ line-specific protein Oct-4. *Nature.* 1990 Mar 29; 344(6265):435-9.
14. Pesce M, Schöler HR. Oct-4: gatekeeper in the beginnings of mammalian development. *Stem Cells.* 2001;19(4):271-8.
15. He W, Li K, Wang F, Qin YR, Fan QX. Expression of OCT4 in human esophageal squamous cell carcinoma is significantly associated with poorer prognosis. *World J Gastroenterol.* 2012 Feb 21; 18(7):712-719.
16. Iki K, Pour PM. Expression of Oct4, a stem cell marker, in the hamster pancreatic cancer model. *Pancreatology.* 2006;6(4):406-13.
17. Tai MH, Chang CC, Kiupel M, Webster JD, Olson LK, Trosko JE. Oct4 expression in adult human stem cells: evidence in support of the stem cell theory of carcinogenesis. *Carcinogenesis.* 2005 Feb;26(2):495-502.
18. Yu H, Fang D, Kumar SM, Li L, Nguyen TK, Acs G, et al. Isolation of a novel population of multipotent adult stem cells from human hair follicles. *Am J Pathol.* 2006 Jun;168(6):1879-88.
19. Cook BE Jr, Bartley GB. Epidemiologic characteristics and clinical course of patients with malignant eyelid tumors in an incidence cohort in Olmstead County, Minnesota. *Ophthalmology.* 1999 Apr;106(4):746-50.
20. Gil J, Stembalska A, Pesz KA, Sasiadek MM. Cancer stem cells: the theory and perspectives in cancer therapy. *J Appl Genet.* 2008;49(2):193-9.
21. Yuan F, Zhou W, Zou C, Zhang Z, Hu H, Dai Z, et al. Expression of Oct4 in HCC and modulation to wnt/beta-catenin and TGF-beta signal pathways. *Mol Cell Biochem.* 2010 Oct;343 (1-2):155-62.
22. Lee TI, Jenner RG, Boyer LA, Guenther MG, Levine SS, Kumar R.M, et al. Control of developmental regulators by Polycomb in human embryonic stem cells. *Cell.* 2006 Apr 21;125(2): 301-13.
23. Clay MR, Tabor M, Owen JH, Carey TE, Bradford CR, Wolf GT, et al. Single marker identification of head and neck squamous cell carcinoma cancer stem cells with aldehyde dehydrogenase. *Head Neck.* 2010 Sep;32(9):1195-201.
24. Hsuan JD, Harrad RA, Potts MJ, Collins C. Small margin excision of periocular basal cell carcinoma: 5 year results. *Br J Ophthalmol.* 2004 Mar;88(3):358-60.
25. Breuninger H, Pesch M, Dietz K, Rassner G. [Quantitative analysis of recurrence and spontaneous regression of basalioma parts left in situ]. *Hautarzt.* 1992 Sep;43(9):561-5.
26. Dellon AL, DeSilva S, Connolly M, Ross A. Prediction of recurrence in incompletely excised basal cell carcinoma. *Plast Reconstr Surg.* 1985 Jun;75(6):860-71.
27. Sussman LA, Liggins DF. Incompletely excised basal cell carcinoma: a management dilemma? *Aust N Z J Surg.* 1996 May;66(5):276-8.