

Clinical Application of Hyaluronic Acid Gel for Reconstruction of Interdental Papilla at the Esthetic zone

S. Sadat Mansouri ^{1✉}, M. Ghasemi ¹, Z. Salmani ², N. Shams ³.

¹Associate Professor, Department of Periodontics, School of Dentistry, Dental Branch, Islamic Azad University. Tehran, Iran

²Dentist

³Postgraduate Student, Department of Periodontics, School of Dentistry, Dental Branch, Islamic Azad University. Tehran, Iran

Abstract

Background and Aim: Interdental papilla reconstruction especially at the esthetic zone is among the most difficult periodontal treatments. Papilla deficiencies may occur following some periodontal surgeries and several techniques, mostly surgical and invasive, have been suggested to correct them. The purpose of this study is to evaluate the clinical application of hyaluronic acid gel for reconstruction of interdental papilla at the esthetic zone.

Materials and Methods: This experimental before and after study was conducted on 11 patients with 21 interdental papilla deficiencies who met the inclusion criteria. After the induction of local anesthesia, less than 0.2 ml hyaluronic acid gel was injected at the respective areas. This procedure was repeated 3 weeks and 3 months later for all the respective areas. Photographs obtained before the treatment and 3 weeks, 3 months and 6 months after the intervention were assessed by Image J software based on image pixels. Data were extracted and changes in the interdental space at the mentioned time points were statistically analyzed using Repeated Measures ANOVA.

Results: Application of hyaluronic acid gel for reconstruction of interdental papilla was successful in a 6-month period. In the second follow up, 10% of subjects showed improvement in interdental papilla reconstruction by 50%. In the third follow up (at 6 months) 43% of samples showed 50% improvement or higher. The mentioned differences were statistically significant. ($p < 0.05$)

Conclusion: Application of hyaluronic acid gel is, to some extent, beneficial for reconstruction of interdental papilla at the esthetic zone and is recommended as a non-invasive technique.

Key Words: Interdental papilla, Hyaluronic acid, Esthetic zone, Tooth

✉ Corresponding author:
S. Sadat Mansouri, Associate
Professor, Department of
Periodontics, School of
Dentistry, Dental Branch,
Islamic Azad University.
Tehran, Iran
S.Sadat.Mansouri@dentiaiu.ac.ir

Received: 22 May 2012

Accepted: 10 April 2013

Journal of Islamic Dental Association of IRAN (JIDAI) Summer 2013 ;25, (3)

Introduction

Interdental papilla reconstruction especially at the esthetic zone is among the most difficult periodontal treatments. Interdental papilla loss or defects have been reported following some periodontal surgeries [1-9].

In such conditions, restoring the esthetics at the anterior region is among patients' expectations from periodontal treatments [1]. This issue can become highly problematic especially in cases with high lip line to the extent that the patient may

avoid smiling. Several surgical techniques have been proposed for reconstruction of interdental papilla. However, these techniques are mostly invasive and unpredictable.

A non-invasive technique with the use of hyaluronic acid gel has been recently proposed. Its manufacturing company claims that this treatment can replace the afore-mentioned invasive surgical procedures and may be successfully used for the reconstruction of dental papilla at the esthetic zone. Hyaluronic acid is an extracellular matrix compo-

nent and the majority of cells are able to produce it during several phases of their cell cycle. The most important function of hyaluronic acid is its involvement in tissue healing and repair. In this phase, hyaluronic acid involves in a series of inflammatory responses (including activation and neutralization). This material stimulates cell proliferation, migration and angiogenesis, re-epithelialization and proliferation of basal keratinocytes and reduces collagen and scar tissue formation [14-15]. Due to the mentioned characteristics, hyaluronic acid is used as an effective medication for treatment of recurrent aphthous ulcers [16], as an adjuvant treatment for gingivitis [17] and to enhance tooth extraction socket healing [18].

Considering the claims of the manufacturer, a study evaluated the effect of this gel on reconstruction of interdental papilla and injected it into 14 areas resulting in more than 94% improvement in papilla reconstruction in 10 cases [19].

Due to the lack of adequate information regarding the efficacy of this material, the present study sought to assess the effect of hyaluronic acid gel on interdental papilla reconstruction at the esthetic zone in patients presenting to the Department of Periodontics, Islamic Azad University, School of Dentistry.

Materials and Methods

In this experimental before and after study, samples were collected by clinical examination. Patients presenting to the Department of Periodontics, Islamic Azad University, School of Dentistry with interdental papilla loss or defects at one or several areas in the anterior maxillary region who met the inclusion criteria were selected for this study. The inclusion criteria were as follows:

- Age range of 20-75 years
- Possession of the maxillary anterior teeth
- Plaque index of below 20% [20]
- The respective teeth had to be free from caries with no fixed prosthesis or orthodontic appliance
- Subjects had to be non-smoker
- No history of systemic disease affecting the periodontal status
- No consumption of drugs causing gingival hyperplasia

Patients were thoroughly informed about the method of conduction of study and a written informed consent was obtained from them. A questionnaire was filled out including demographic characteristics and confirmation of inclusion criteria. Periodontal status was evaluated according to Maynard's [21] classification and marginal tissue recession was assessed using Miller's classification [22]. A periodontal radiograph was obtained from the respective teeth using parallel technique and the bone crest-contact point distance [23] was calculated and recorded. In the next step, the first phase of periodontal treatment was performed for the patients, if required. Before the application of gel, the area was photographed using Eos 450 D Canon digital camera. A measurement index (reference object) was used to match the photographs obtained at different time points. Using Image J software, the size (area) of open gingival embrasure spaces was calculated based on pixel size and the formula below according to Becker et al, [19]:

$$f = \%change \frac{S_{in} - S_{fin}}{S_{in}} = 1 - \left[\frac{f_{in}}{f_{fin}} \right]^2 \frac{N_{fin}}{N_{in}}$$

$S_{initial}$ = Is the area of the gap before treatment/ S_{final} = Is the area of the gap after treatment/ $N_{initial}$ = Is the number of gap image pixels before treatment/ N_{final} = Is the number of gap image pixels after treatment/ $L_{initial}$ = Is the size of the reference object on the image before treatment/ L_{final} = Is the size of the reference object on the image after treatment

Where S initial is the area of the gap before treatment, S final is the area of the gap after treatment, N initial is the number of gap image pixels before the treatment, N final is the number of gap image pixels after the treatment, L initial is the size of the reference object on the image before treatment and L final is the size of the reference object on the image after treatment.

After the administration of local anesthetic agent, less than 0.2 ml of the hyaluronic acid gel was injected at the respective sites 2-3 mm apical to the coronal tip of the papilla. The patients were discharged and requested not to brush their teeth at the day of injection and resume oral hygiene the day after using a soft toothbrush at the anterior teeth and place it coronal to gingival margin. The patients were asked not to use dental floss at the treatment sites. Three weeks later the treatment

area was photographed again and utmost effort was made to use the same distance and horizontal and vertical angles during photography:

A.If the black triangle was not observed at the interdental space, the patient would be followed up at three and 6 months and photographed again at the mentioned time points.

B.If the black triangle was observed at the interdental space, another gel injection would be performed and in case of no improvement, would be repeated once more (injections would be performed for a maximum of three times according to the manufacturer's instructions). Patients would be followed up and photographed at 3 and 6 months.

The obtained data were statistically analyzed using Repeated Measures ANOVA.

Results

A total of 21 interdental papillae in 11 patients including 3 males and 8 females with a mean age of 37.5 ± 14.4 yrs (range 22-61 yrs.) were evaluated. Of 21 understudy papillae, 16 were in females (76.2%) and 5 (23.8%) were in males. None of the cases had diastema or space in between their understudy teeth. All subjects were followed up until the completion of treatment

and no complication, hypersensitivity or allergy was noted. In terms of periodontal status, 18 papillae (86%) were type I and the remaining were type III. In 15 papillae (71.4%) marginal gingival recession was not observed. In 3 papillae (14.3%) type I and in another 3 type III marginal gingival recession was noted. On radiographic examination, the mean bone crest-contact point distance was 5.04 ± 1.5 mm. Percentage change of interdental papilla

reconstruction at different follow up times is presented in Table 1.

Table 1 shows that at the first follow up (3 weeks after the injection), 1-15% improvement in papilla reconstruction with a mean of $3.38 \pm 3.07\%$ was observed. In the second follow up (three months later) 12-83% improvement with a mean of $29.52 \pm 18.72\%$ and at the third follow up (6 months after the injection), 22-100% improvement with a mean of $47.33 \pm 20.20\%$ were noted.

In the second follow up, approximately 10% of subjects showed 50% improvement; while in the third follow up (at 6 months), about 43% of samples demonstrated improvement in interdental papilla reconstruction by over 50% (Figure 1).

The effect of underlying factors such as gingival recession, periodontal status, bone crest-contact point distance, tight or loose contact and age was also evaluated and statistical analyses revealed that interdental papilla reconstruction did not have a significant correlation with the above-mentioned factors except for age.

A significant association was found between age and papilla reconstruction ($p < 0.01$) and averagely, $58.72 \pm 20.84\%$ improvement was observed in patients younger than 40 years of age; while, this rate was $34.80 \pm 9.55\%$ in subjects over 40 years old.

Sulcus depth was only measured at baseline for inclusion of subjects and was not evaluated in further steps since this variable could not be measured in the first months after treatment. Considering the conduction of first phase of periodontal treatment in all patients or the need for previous surgery, sulcus depth was normal at baseline in all subjects.

Table 1. Percentage change of interdental papilla reconstruction at different follow up times

Follow up	Papilla reconstruction Number	Minimum (percentage)	Maximum (percentage)	Mean and standard deviation (percentage)
Three weeks	21	1	15	$3/38 \pm 3/07$
Three months	21	12	83	$29/52 \pm 18/72$
Six months	21	22	100	$47/33 \pm 20/20$

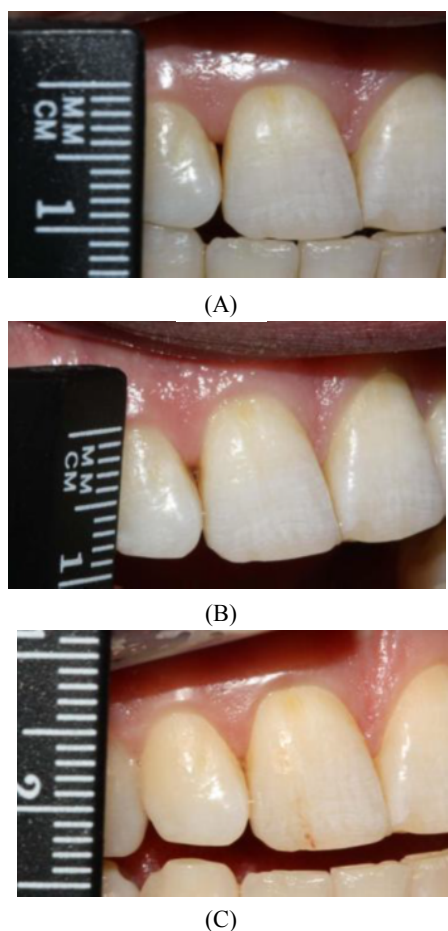


Figure 1. A) Before the injection. Papilla deficiency at the gingival embrasure between maxillary right central and lateral incisors, B) Improvement by 83% at 3 months follow up, C) Papilla reconstruction improvement by 100% at 6 months follow up.

Discussion

The study results demonstrated that application of hyaluronic acid gel was successful for interdental papilla reconstruction at 6 months follow up. Rate of interdental papilla reconstruction at the maxillary anterior region was significant compared to baseline ($p < 0.05$).

Esthetic problems after the loss of interdental papilla especially following periodontal surgeries have been extensively reported in the literature [1, 10-13]. In order to resolve this issue, several methods have been proposed to fill up this space including periodic curettage [10], Beagle's technique [11], a combination of Roll technique and papilla preservation [12] and pedicle flap (comprising of a semi-lunar incision and a coronally advanced flap) [13].

However, these techniques are all invasive and mostly unpredictable. Application of non-invasive techniques such as the use of commercially available hyaluronic acid gel can replace the conventional invasive methods.

Literature review revealed that to date, only one study has evaluated the effect of this substance on interdental papilla reconstruction [19]. Becker et al. [19] concluded that injection of hyaluronic acid gel as a safe material significantly decreased the interdental black triangle in the esthetic zone. This finding was similar to our obtained result.

In the study by Becker et al, 14 papillae (including 4 papillae adjacent to teeth and 10 papillae at the implant sites) were evaluated and in 70% of samples (10 papillae), 94% improvement was achieved. However, in the present study 21 interdental papillae (all adjacent to teeth) were evaluated and in the last follow up (at 6 months) more than 50% improvement was noted in 43% of cases. Thus, it seems that chances of filling up the interdental space and reconstruction of papilla increase in time.

It should be mentioned that the study by Becker et al, was a pilot study and in cases where the patients were cooperative the follow up continued by up to 25 months; whereas, in the present study maximum duration of follow up was 6 months (at 3 weeks, 3 months and 6 months) and similar for all patients. Although the duration of follow up in the present study is a positive point, longer follow ups will further confirm the positive effect of time on papilla reconstruction. Furthermore, duration of follow up was not the same for all understudy patients in Becker et al, study. Number of injections was not the same either as some areas (8 sites) received 2 injections while some others (6 sites) required a third injection as well. However, in our study all patients received three injections.

Among the underlying factors evaluated in the present study, only age had a significant correlation with the rate of papilla reconstruction; which may be attributed to the small sample size and its dispersion ($p < 0.01$). To date, no comparative study has been conducted on this material and other invasive techniques. Based on the available literature, in case of gaining approval through further assessment, it can replace conventional invasive methods for papilla reconstruction.

Jaiswal et al, [24] used subepithelial connective tissue graft along with coronally advanced flap for reconstruction of dental papilla. At 6 months follow up, they demonstrated significant improvement. They reported this result in patients with type I Tarnow classification. Thus, considering the traumatic and invasive nature of the mentioned method, use of a safer and less invasive technique such as the application of hyaluronic acid gel can be considered as a suitable alternative. It should be noted that hyaluronic acid is an efficient material for cell proliferation, migration and angiogenesis and plays an important role in tissue repair and reduction of scar formation [14,15]. Hyaluronic acid is a synthetic material and can be used with no drug interference. It does not need cutaneous sensitivity testing and has FDA approval [19].

Since interdental papilla reconstruction is a challenging issue in implant treatments, this non-invasive technique might be helpful for such cases especially at the esthetic zone.

The present study results and those of Becker et al. can be of great help in this regard and pave the way for determining the role of influential factors such as the anatomy of the region, interdental papilla morphology and time and number of injections in success rate of this treatment.

Conclusion

Application of hyaluronic acid gel was somehow effective for interdental papilla reconstruction and may be used as a non-invasive technique for reconstruction of interdental papilla by dentists.

References

- 1- Azzi R, Etienne D, Carranza, F. Surgical reconstruction of the interdental papilla. *Int J Periodont Rest Dent*. 1998 Oct; 18(5):466-473.
- 2- Becker W. Esthetic soft-tissue augmentation adjacent to dental implants. *Compend Contin Educ Dent*. 2001 Mar;22(3):250-2, 254, 256.
- 3- Cardaropoli G, Lekholm U, Wennstrom JL. Tissue alterations at implant - supported single – tooth replacements: a 1-year prospective clinical study. *Clin Implants Res*. 2006 Apr; 17(2):165-71.
- 4- Cho Hs, Jang Hs, Kim Dk, Park JC, Kim Hj, Choi Sh, et al. The effects of interproximal distance between roots on the existence of interdental papillae according to the distance from the contact point to the alveolar crest. *J Periodontol*. 2006 Oct; 77(10):1651-7.
- 5- Choquet V, Hermans M, Adriaenssens P, Daellemans P, Tarnow DP, Malevez C. Clinical and radiographic evaluation of the papilla level adjacent to single – tooth dental implants. A retrospective study in the maxillary anterior region. *J Periodontol*. 2001 Oct; 72(10):1364-71.
- 6- Goldstein M, Boyan BD, Schwartz Z. The Palatal advanced flap: A pedicle flap for primary coverage of immediately placed implants. *Clin Oral Implants Res*. 2002 Dec;13(6):644-50.
- 7- Kois Jr. Altering gingival levels: The restorative Connection part I: Biologic variables. *J Esthetic Dent*. 1994;6:3-9.
- 8- Nemcovsky CE, Moses O, Artzi Z. Interproximal papillae reconstruction in maxillary implants. *J Periodontol*. 2000 Feb; 71 (2):308-14.
- 9- Tarnow DP, Eskow RN, Zamzok JA. Esthetics and implant dentistry. *Periodontol*. 2000. 1996 Jun; 11: 85-94.
- 10- Shapiro A. Regeneration of interdental papilla using periodic curettage. *Int J Periodont Rest Dent*. 1985; 5: 27-33.
- 11- Beagle JR. Surgical reconstruction of the interdental papilla. *Int J Periodont Rest Dent*. 1992;12:145-152.
- 12- Evian C, Corn H, Rosenberg E. Retained interdental procedure for maintaining anterior esthetics. *Compend Contin Educ Dent*. 1985 Jan; 6(1):58-64.
- 13- Han TJ, Takei HH. Progress in gingival papilla reconstruction. *Periodontol*. 2000. 1996 Jun; 1: 65-8.
- 14- Chen J, Abatangelo G. Functions of hyaluronan in wound repair. *Wound Repair Regen*. 1999 Mar-Apr; 7(2):79-89.
- 15- Toole BP. Hyaluronan and its binding proteins, the hyaladherins. *Current Opinion in Cell Biology* 1990 Oct; 2 (5):839-44.
- 16- Nolon A, Baillie C, Badminton J, Rudralingam M, Seymour RA. The efficacy of topical hyaluronic acid in the management of recurrent aphthous ulceration. *J Oral Pathol Med*. 2006 Sep; 35(8):461-5.
- 17- Jentsch H, Pomowski R, Kundt G, Göcke R. Treatment of gingivitis with hyaluronan, *J Clin Periodontol*. 2003 Feb;30(2):159-64.
- 18- Mendes R, A. B Silva G, F. Lima M, V. Calliari M, P. Almeida A, B. Alves J, et al. Sodium hyaluronate accelerates the healing process in tooth sockets of rats. *Arch Oral Biol*. 2008 Dec;53(12):1155-62.

- 19-Becker W, Gabitov I, Stepanov M, Kois J, Smidt A, E, Becker B. Minimally invasive treatment for papillae deficiencies in the esthetic zone: A pilot study. *Clini Implant Dent and Related Res.* 2010 Mar; 12(1):1-8.
- 20-O'leary TJ, Drake RB, Naylor JE. The plaque control record, *J Periodontal.* 1972 Jun;43(1):38.
- 21-Maynard JC. Mucogingival consideration for the adolescent patient in periodontal therapy, clinical approaches and evidence of success. Illinois: Quintessence publishing CO. Inc; 1998;292-93.
- 22-Miller PD Jr. A classification of marginal tissue recession. *Int J Period Rest Dent.* 1985;5(2):8-13.
- 23-Dennis P. Tarnow, Annew. Manger, Paul Fletcher. The effect of the distance from the contact point to the crest of bone on the presence or absence of the interproximal dental papilla. *J Periodontal.* 1992 Dec; 63: 995-996.
- 24-Jaiswal P, Bhongade M, Tiwari I, Chavan R, Banode P. Surgical reconstruction of interdental papilla using Subepithelial connective tissue graft (SCTG) with a coronally advanced flap. *J Contemp Dent Pract.* 2010 Dec 1; 11(6):E049-57.

