

Evaluation of the Diagnostic Efficacy of Intra Oral Digital Radiography With and Without Zoom Option Software in the Detection of Occlusal Dentinal Caries: An in Vitro Study

S. Mehr-Alizadeh ^{1✉}, D. Sadri ², S. Nemati ³, S. Sarikhani ⁴, A. Zafarfazeli ⁵.

¹Assistant Professor, Department of Oral and Maxillofacial Radiology, School of Dentistry, Azad University, Tehran, Iran.

²Associate Professor, Department of Oral Pathology, School of Dentistry, Azad University, Tehran, Iran.

³Assistant Professor, Department of Operative Dentistry, School of Dentistry, Azad University, Tehran, Iran.

⁴Resident, Department of Oral and Maxillofacial Radiology, School of Dentistry, Shahid Beheshti University of Medical Sciences, Tehran, Iran.

⁵Resident, Prosthodontics, School of Dentistry, Shahed University, Tehran, Iran.

Abstract

Background and Aim: The purpose of this study was to evaluate the diagnostic precision of zoom option of Cygnus Ritter CCD intraoral digital sensor compared to original digital radiography in the detection of occlusal dentinal caries.

Materials and Methods: Eighty-six extracted premolars with no apparent clinical caries were selected. Two methods were used for radiography; namely, digital radiography using a Cygnus Ritter CCD sensor and then zoom option was applied to the original radiographs. Four maxillofacial radiologists observed the original digital and the same radiographs with zoom option to detect occlusal dentinal caries subsequently recording it in a five-grade scale. Microscopic sections evaluated by a pathologist were used as the gold standard for caries detection. The data were analyzed with a proportion test and processed with SPSS maxillofacial 14 software.

Results: Statistical analysis showed a sensitivity of 52.2% (71) (CI: 95%) for zoom option in the detection of occlusal dentinal caries ($P < 0.05$). The specificity was shown as 68.8% (143) ($P > 0.05$). The ppv was calculated as 52.2% (179) ($P < 0.05$) and npv as 68.8% (236) ($P < 0.05$) and the accuracy was 62.2% (214) ($P < 0.05$).

Conclusion: The zoom option of Cygnus Ritter CCD sensor showed a significantly higher diagnostic sensitivity, ppv, npv and accuracy compared to original digital radiographs, but the zoom option of that sensor did not show a significantly higher diagnostic specificity compared to original digital radiographs.

Key Words: Dentinal caries, Digital radiography, Digital enhancement, Image processing, Zoom

✉ **Corresponding author:**
Dr. Mehr-Alizadeh S, Assistant Professor, Department of Oral and Maxillofacial Radiology, School of Dentistry, Azad University, Tehran, Iran
Sandramehr@yahoo.com

Received: 12 Jan 2011

Accepted: 11 Oct 2011

Journal of Islamic Dental Association of IRAN (JIDAI) / Spring 2012 / 24 / (2)

Introduction

Diagnosis of primary tooth caries on the occlusal surface is more difficult in comparison to proximal surface caries and flat surface caries [1]. Passing of time makes this type of caries form

the most proportion of the total caries; therefore, correct diagnosis of it is of highest importance [2-3]. Based on Wenzel's study in 1991 [4] and another study by the same researcher in 1993 [5] and the evaluations performed by Holt and Ket-

ley in 1993 [6] and also a study carried out in 2001 in Koln, Germany [7] it may be stated that the advantage of digital radiography over film radiography, especially in tooth decay is a clear concern that cannot be denied. The reason may be the progress in computer software and hardware. In the present circumstances, using digital radiography in order to eliminate the shortcomings related to film radiography [8] is rising and this matter points to the necessity of knowing the efficacy of different software options to seek a reliable and also quicker method to diagnose tooth decay.

The manufacturers of intra oral digital radiography devices claim that applying the abilities of this device increases the diagnostic accuracy, but there is still not enough clinical evidence regarding the diagnostic efficacy of different software options [9]. The objective of this study was the in vitro evaluation of the diagnostic efficacy of intra oral digital radiography zoom option in the diagnosis of dentinal occlusal decay.

Materials and Methods

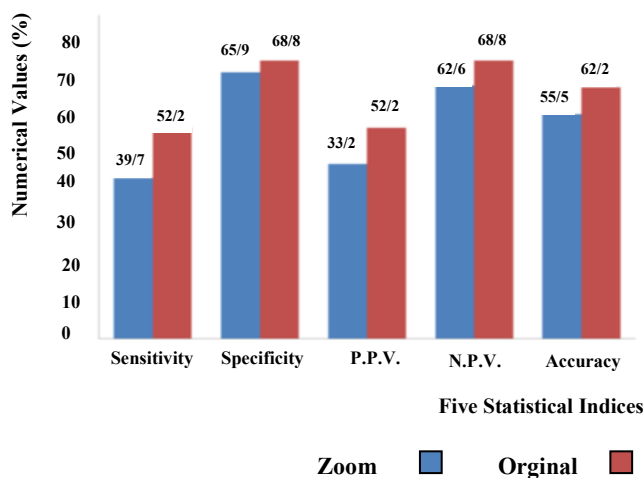
This was an experimental in vitro study. Eighty six extracted human premolar teeth were evaluated clinically. Eighty of these teeth which had no occlusal decay were included in the study. From each of the selected samples a digital radiography was prepared by an intra oral radiography device (Orix 65, ARDET, Italy) with a CCD sensor (Charge Coupled Device) and a 20×30 cm active area (Ritter, USA and Cygnus media 3.0) and the parallel technique. The radiation ray time was 0.2 sec and the images were composed of 912 H×1368 V pixels. Each pixel is equal to 22 micron. In the next step, the digital images were showed by Cygnus media 2002 software. The images of the teeth were once displayed as regular and once by zoom option 204% on a 17 inch SVGA monitor (LG, Flatron 700B, LG Electronics) with a 800×600 pixel image resolution. Afterwards, four experienced radiologists observed the images and reported their opinion regarding dentine occlusal decay based on a five

scale confidence score (0, No decay; 1, possibly no decay; 2, suspicious; 3, possibly has decay; 4, definitely has decay) in information sheets 2 and 3. After radiography of the teeth, the samples were cut by a diamond bur (Z & D) mesiodistally under running water. In the next step, the samples were held in 10% formalin for one week, then maintained in a solution composed of 700 cc distilled water, 200 cc formalin and 100 cc pure formic acid for 25-30 days. This solution was changed every 3 days. After this time passed and the teeth were decalcified, they were brought out of the solution and were rinsed with water then neutralized with lithium carbonate. After passing through the tissue circulation stages, 5 micron slices of paraffin blocks were prepared mesiodistally and four microscopic slides were colored with hematoxylin and eosin and then were evaluated regarding dentinal decay under ALPHA PHOT 2 light microscope (Ys-Nikon) and a ×10 and ×40 magnification by a maxillofacial pathology specialist. The premolar tooth with dentinal decay was selected as the positive control group and existence or absence of dentinal decay on the occlusal surface was evaluated according to the mentioned criteria in the reference books and comparison with the control sample [10]. In case the four prepared slides of each tooth sample showed tooth decay, it was selected as the positive sample and the results were recorded in information sheet number 2 and the obtained findings were statistically analyzed by proportion tests. After determination of the normal and decayed samples in each of the methods, in order to compare with the gold standard, the agreement table was applied to define the sensitivity, specificity, positive predictive value, negative predictive value and accuracy for each method based on the relative formula. To compare the above mentioned criteria between methods, the proportion test was used. $P < 0.05$ was considered statistically significant. SPSS 14 for Windows (SPSS Inc., Chicago, Illinois) was used for analysis.

Results

According to the statistical analysis, the sensitivity of diagnosis of dentinal decay on the occlusal surface using digital radiography was mainly 54 (39.7%) (confidence interval: 95%, 42.1%-37.3%) and the sensitivity of diagnosis of dentinal decay on the occlusal surface using digital radiography with zoom option software was 71 (52.2%) (CI: 95%, 50%-54.4%). The sensitivity of digital radiography with zoom option software was significantly higher statistically ($p < 0.05$). The specificity of diagnosis of dentinal decay on the occlusal surface using digital radiography was mainly 137 (65.9%) (CI: 95%, 64.7%-67.1%) and the specificity of diagnosis of dentinal decay on the occlusal surface using digital radiography with zoom option software was 143 (68.8%) (CI: 95%, 67.5%-70.1%) showing no significant difference between the two above mentioned methods statistically ($p > 0.05$). The positive predictive values (PPV) for diagnosis of occlusal surface dentinal decay using digital radiography and digital radiography with zoom option software was 148 (43.2%) (CI: 95%, 40.8%-45.6%) and 179 (52.2%) (CI: 95%, 50%-54.4%), respectively. These figures demonstrate a significantly higher PPV for digital radiography with zoom option software compared to digital radiography statistically ($p < 0.05$). The negative predictive values (NPV) for diagnosis of occlusal surface dentinal decay using digital radiography and digital radiography with zoom option software was 215 (62.6%) (CI: 95%, 61.4%-63.8%) and 236 (68.8%) (CI: 95%, 67.5%-70.1%), respectively pointing to the fact that NPV in digital radiography with zoom option software is significantly higher in comparison to digital radiography statistically ($p < 0.05$). The accuracy for diagnosis of occlusal surface dentinal decay using digital radiography and digital radiography with zoom option software was 191 (55.5%) (CI: 95%, 54.6%-56.4%) and 214 (62.2%) (CI: 95%, 61.4%-63%) mentioning a higher statistical significance in digital radiography with zoom option software ($p < 0.05$).

(Graph 1).



Graph 1: Comparison of Se, Sp, PPV, NPV and accuracy between digital radiography and digital radiography with zoom option software

Discussion

In this study, sensitivity, positive predictive value, negative predictive value and accuracy for digital radiography with zoom option software was significantly higher than digital radiography ($p < 0.05$), but no significant difference was detected in the specificity between these two radiography methods ($p > 0.05$). The studies which have evaluated the diagnostic ability of digitized conventional radiography and the routine radiography method; namely, Ohki et al. in 1994 [11], Moystad et al. in 1995 [12], Attaelmanan et al. in 2000 [13] and Kunzel et al. in 2003 [14], emphasize on the higher ability of digitized radiography. Based on the mentioned reports and the statements in the present studies, the studies are moving from comparison of conventional (film) radiography and digital radiography more commonly towards evaluating the ability of different progressive softwares.

In a study conducted by Hintze et al. in 1994, the superiority of digital radiography in the diagnosis of dentinal decay of the occlusal surface was revealed [15]. Verdon shot et al. announced that in enamel decay, the sensitivity and specificity do not change by manipulation of the images,

but increase in sensitivity and decrease in specificity occurs in dentinal decay [16] which is congruent with our study.

In Kositbowornchai et al.'s study in 2003, they evaluated the zoom option software on root fractures and regular (1:1), zoom out (1:2) and zoom in (2:1) images were evaluated and discussed. The results showed that the sensitivity increased in the two zoomed out and zoomed in images, but the specificity decreased in both of the zoomed images which are in agreement with the results of our study [17]. A similar study in 2004 conducted by Kositbowornchai et al. evaluated the diagnostic ability of regular digital images and their authentication zoom, pseudo color and sharpness option softwares. This study demonstrated no significant difference between the softwares and the regular images regarding diagnosis of occlusal decay statistically [15]. Of course these results are not concordant to our study. The reason for this incongruency may possibly be the result of the different sensors and softwares used for these studies. In 1991, Wenzel et al. [16] and also Mc David and Dove found no improvement using manipulated images in the diagnosis of caries; surely, in the present study only specificity showed a statistically significant difference [17].

Ohki et al. reported a significant decrease in diagnostic accuracy when the observers had the permission to manipulate the images [18]. It seems that the visual system gets used to the usually observed images and the previous visual experiences prevent the observer from the correct diagnosis when the image is manipulated.

White and Yoon supervised a study on Shick Technology's digital sensor, in which manipulation increased the specificity and decreased the sensitivity. They believed that these changes were due to the doubt and hesitation in the definite diagnosis as a result of inacquaintance of the users with the new system and vice versa, their high experience with the regular radiography images which certainly disagrees with this study's results [19].

Regarding the expanding studies in the field of caries diagnosis and the importance of this matter, finding a more reliable and also in agreement with the improvement of technology is an important and inevitable concern.

It is obvious that education of the future dentists and also gaining experience and skill in using new technologies such as digital radiography and related softwares and preparing the essential circumstances in the faculties may be a new and great leap towards this objective. Based on the manufacturer's claim, digital radiography with different software options such as reverse contrast, zoom and pseudo color are in agreement with improving the diagnostic efficacy, but there is not enough clinical evidence regarding their diagnostic efficacy [5]. Therefore, paying attention to this matter may lead to finding a new and reliable method for the diagnosis of oral and dental lesions. The present study was aimed towards such an intention and we reached the conclusion that the sensitivity, PPV, NPV and accuracy for digital radiography with zoom option software was significantly higher than digital radiography, but no significant difference was detected in the specificity between these two radiography methods. Generally, radiographic evaluation in diagnosis is a very difficult matter and many different factors have influence on the observer such as the imaging technique; digital or film [12], the monitor or the type of film utilized [20], image manipulation [12, 21], observing circumstances [22, 23] and the observer's experience [20, 24-26]. Thus, in addition to the observing conditions such as the visual circumstances, it seems that using the latest technology in monitor, sensor and the best softwares with an appropriate design towards perception of an image; subsequently, causing accurate diagnoses of different lesions such as effective caries. A more important issue which has been pointed at in different studies in addition to acquaintance of the observers with the sensor, monitor and other software factors is the experience of the observer in using digital images and especially the related

softwares which have a major role in the authenticity and accuracy of the diagnosis of the lesions [20, 24-26]. It appears that the observer who has more experience in the inspection of digital images and works with various softwares has a higher diagnostic efficacy in the diagnosis of lesions by digital radiography in comparison with a person whose work life has mostly been with radiographic films. Besides, the gestalt psychology was first mentioned by Max Wertheimer (1880-1948) a German psychologist. He believed that the perception is always ready to be organized towards certain natural tendencies which based on the opinion of most psychologists, these natural tendencies are the result of experiences which have been learned through years of life [27, 28]. Psychologists believe that one of the factors that make people pay attention to a motive is their perception which is the psychological alertness and structure of an individual; generally, an acquired potency [27]. In the field of the size of the image, the general perception is based on the fact that the details of a larger image are better and easier seen than the details of a smaller image; therefore, we may assume that dentinal caries of the occlusal surface which are a part of the radiographic image will be better detected when the image is larger (the effect of zoom option software).

Surely, based on the human's complicated visual perception and the factors influencing it such as various visual errors, further studies are necessary in this field and other software options such as pseudo color which has been less discussed.

Conclusion

This study showed a significantly higher sensitivity, positive predictive value, negative predictive value and accuracy in digital radiography with zoom option software compared to digital radiography. On the other hand no significant difference was observed in the specificity between these two radiography methods.

Acknowledgment

We appreciate the assistance of Dr. Talaeepour, Dr. Khamenian and Dr. Peymani who helped us sincerely in this study.

References

- 1-Ahluwalia KP, Chanq B, Joseph SPK, LallaE, LamsterIB. Oral disease experience of older adults seeking oral health services. *Gerodontology*. 2010 Jun;27(2):96-103.
- 2-dward J. Swift, JR. Art and science of operative dentistry. Fifth ed. 2006 Chapel Hill, North Carolina: Mosby; 48.
- 3-Bergman G, Linden LA. The action of the explorer on incipient caries. *Sven TandlakTidskr* 1969 Oct; 62(10):629-34.
- 4-Wenzel A, Larsen MJ, Fejerskov O. Detection of occlusal caries without cavitation by visual inspection, film-, xero-, and digitized radiographs. *Caries Res*. 1991; 25(5):365-71.
- 5-Wenzel A. computer aided image manipulation of intra oral radiographs to enhance diagnosis in dental practice. *Int Dent J*. 1993 Apr; 43 (2):99-108.
- 6-Ketley CE, Holt RD. Visual and radiographic diagnosis of occlusal caries in first permanent molars and in second primary molars. *Br Dent J*. 1993 May 22; 174(10):364-70.
- 7-Rainer Haak, Micheal J. Conventional and digital and contrast-enhanced bitewing radiographs in the decision to restore approximal carious lesions. *Caries Res*. 2001; 35(3):193-199.
- 8-Wenzel A, Hintze H, Mikkelsen L, Mouyen F. Radiographic detection of occlusal caries in non-cavitated teeth. A comparison of conventional film radiographs, digitized film radiographs and Radio VisioGraphy. *Oral Surg Oral Med Oral Pathol*. 1991 Nov; 72(5):621-60.
- 9-Withe & pharaoh, Oral radiology principles and interpretation, 6th ed. China: Mosby; 2009, 235-239.
- 10-Cawson RA, Binnie WH, Barret Aw, wright J. Oral Disease. 3rd ed. USA: Mosby; Zool.
- 11-OhkiM, Okono T, Nakamura T. Factors determining the diagnostic accuracy of digitized

- conventional intra-oral radiographs. *DentoMaxillo Facial Radiol.* 1994 May; 23(2):77-82.
- 12-Moystad A, Svanae DB, Larheim TA. Effect of image magnification of digitized bitewing radiographs of approximal caries detection in-vitro Study. *DentomaXill of AcialRadiol.* 1995 Nov; 24(4):255-9.
- 13-Attaelmanan A, BorgE, Grondahl HG. Digitization and display of intra-oral films. *Dentomaxillo Fac Radiol.* 2000 Mar; 29(2):97-102.
- 14-Kunzel A, Scherkowski D. Visually detectable resolution of intra oral dental films. *Dentomaxillofacradiol*, 2003 Nov; 32(6):385-9.
- 15-Hintze H, Wenzel A, Jones C. In vitro comparison of D-and E-speed film radiography RVG, and visualix digital radiography for the detection of enamel approximal and dentinal occlusal caries lesions. *Caries Res.* 1994; 28(5): 363-7.
- 16-Verdon shot EH, Koijpers JM, Polder BJ, Deleng-worm MH, Bronkhorst EM. Other effect of digital-gray-scale modification on the diagnosis of small approximal carious lesion. *J Dent.* 1992 Feb; 20(1):44-9.
- 17-Kositboworn chai S, Sikram S, Nuansakul R, Thinkhamrop B. Root fracture detection on digital images effect of the zoom function. *Dento-Tromatol.* 2003; 19:154-159.
- 18-OhkiM, Okono T, Nakamura T. Factors determining the diagnostic accuracy of digitized conventional intra-oral radiographs. *Dento Maxillo Facial Radiol.* 1994 May; 23(2):77-82.
- 19-Sc white and DC Yoon. Comparative performance of digital and Conventional image for detectionong proximal surface caries. *Dentomaxillofac Radiol.* 1995 May; 24(2):121-7.
- 20-Moystad A, Svanaes DB. The effect of cathode ray tube display format on observer performance in dental digitized radiography: comparison with plain film. *Dentomaxillofacial Radiol.* 1994 Nov; 23(4):206-10.
- 21-Wenzel A. Effect of image enhancement for detectability of bone lesions in digitized intra oral radiographs. *Scand J Dent Res.* 1988 Apr; 96(2):149-60.
- 22-White SC. Caries detection with xeroradiographs. The influence of observer experience. *Oral Surg Oral Med Oral Pathol.* 1987 Jul; 64(1):118-22.
- 23-RamanathanGp. Diagnosis of dental caries: A comparison of three radiographs viewing techniques. *J ClinPediatr Dent.* 1999 Spring; 23(3): 235-45.
- 24-De Araujo EA, Castilho JC, Medici Filho E, de Moraes ME. A Comparison of direct digital and conventional imaging with ekta speed plus and Insight films for the detection of approximal caries. *Am Dent.* 2005 Aug; 18(4):241-4.
- 25-Uprichard KK, Potter BJ, Russell CM, Schaffer TE, Adair S, Weller RN. Comparison of direct digital and conventional radiography for detection of the proximal surface caries in the mixed dentition. *Pediatr Dent.* 2000 Jan-Feb; 22(1):9-15.
- 26-K Syriopoulos, GCH Sanderink. Radiographic detection of approximal caries: a comparison of dental films and digital imaging system. *DentomaxillofacRadiol.* 2000Sep; 29(5):312-318.
- 27-Parsa M, Principles of psychology (General psychology), 1th ed. Tehran: Sokhan; 1378, 197-200.
- 28-Piers DL. Howe. Whites effect: Removing the junctions but preserving the strength of the illusion. *Harvard Medical School. Perception* 2005Oct; 34(5):557-564.