

# A Comprehensive Review of the Convergence of Artificial Intelligence and Cone Beam Computed Tomography in Endodontics: Advancements in Diagnostic and Therapeutic Success

Tara Naghshbandi <sup>1</sup>, Behnam Bolhari <sup>2</sup>, Zeynab Afzali <sup>3</sup> 

<sup>1</sup> Dental Research Center, Shahid Beheshti University of Medical Sciences, Tehran, Iran

<sup>2</sup> Professor Department of Endodontics, School of Dentistry, Tehran University of Medical Sciences, Tehran, Iran

<sup>3</sup> Department of Endodontics, Dental Research Center Dentistry Research Institute, Faculty of Dentistry, Tehran University of Medical Science, Tehran, Iran

## Abstract

**Background and Aim:** Artificial Intelligence (AI) models, such as Convolutional Neural Networks (CNNs) and Artificial Neural Networks (ANNs), are increasingly being utilized to analyze Cone Beam Computed Tomography (CBCT) images. This comprehensive review aims to explore the diagnostic and prognostic accuracy of AI when applied to CBCT imaging in endodontic practices, highlighting its potential to enhance clinical outcomes.

**Materials and Methods:** A comprehensive electronic literature search was conducted using prominent electronic databases, including Google Scholar, PubMed, Medline, and Scopus. The search strategy spanned publications from 2000 to the present, employing targeted keywords such as "AI", "machine learning", "deep learning", "endodontics", "CBCT", "advanced analytics", "computational linguistics", "automation", "intelligent agents", "probabilistic reasoning", "CNN", and "ANN".

**Results:** The initial search identified a total of 2072 articles, of which 37 met the stringent inclusion criteria for this review. The analysis revealed a significant concentration of research on key areas within endodontics, including the verification of working lengths, detection and projection of periapical pathologies, assessment of root canal morphologies, and predictions related to root fractures. Recent studies emphasize the growing focus on improving the precision and efficiency of endodontic diagnostics through AI-powered CBCT applications.

**Conclusion:** The findings of this review underscore the pivotal role that AI-enhanced CBCT imaging plays in advancing diagnostic accuracy and improving prognostic evaluations in endodontics. The integration of AI with CBCT heralds a new era of precision in endodontic care, facilitating more efficient workflows and standardized diagnostic practices while reducing the potential for human error.

**Key Words:** CBCTC, Convolutional Neural Networks, Deep Learning Models, Endodontic Prognosis, Machine Learning.

 Corresponding author:  
Zeynab Afzali, Department of  
Endodontics, Dental Research  
Center Dentistry Research  
Institute, Faculty of Dentistry,  
Tehran University of Medical  
Science, Tehran, Iran

afzalizeynab8@gmail.com

Received: 22 Jan 2024

Accepted: 5 April 2024

➤ **Cite this article as:** Naghshbandi T, Bolharo B, Afzali Z. A Comprehensive Review of the Convergence of Artificial Intelligence and Cone Beam Computed Tomography in Endodontics: Advancements in Diagnostic and Therapeutic Success. *J Iran Dent Assoc.* 2024; 36(1-2):13-28. [10.34172/jida.A-10-1-1002](https://doi.org/10.34172/jida.A-10-1-1002)

## Introduction

Endodontics is a specialized branch of dentistry focusing on the diagnosis and treatment of conditions affecting the dental pulp and surrounding tissues (1). For effective endodontic therapy, achieving an accurate diagnosis and making a well-designed treatment plan are critical. Traditionally, two-dimensional (2D) imaging techniques such as periapical and bitewing X-rays have been the primary tools for endodontic diagnosis (2,3). However, these 2D images come with limitations, including distortion, overlapping anatomical structures, and the absence of depth information. Such drawbacks make it difficult to accurately visualize complex root canal systems, detect periapical lesions, and evaluate treatment outcomes (4,5).

In recent years, the introduction of three-dimensional (3D) imaging technologies, particularly Cone Beam Computed Tomography (CBCT), has transformed the field of endodontic imaging (6). CBCT offers high-resolution, volumetric images that allow for detailed visualization of root canal anatomy, detection of fractures, and more accurate assessment of periapical pathologies (7–10). This 3D modality addresses many of the limitations posed by conventional radiographs, as it enables the examination of dental structures from multiple angles, providing clinicians with a more comprehensive understanding of the anatomical complexities (11). Consequently, CBCT has become an invaluable tool in handling complex cases, improving diagnostic precision, and enabling more accurate treatment planning in endodontic procedures. Despite these advancements, manually interpreting CBCT images remains a time-consuming process, subject to variability between operators, and prone to human error (12). This creates a growing need for advanced technologies to streamline the diagnostic workflow and enhance its accuracy. Additionally, traditional manual analysis of CBCT images may overlook subtle anatomical variations, such as accessory canals or uncommon curvatures, further highlighting the importance of improving diagnostic methods (13).

Artificial Intelligence (AI) consists of a neural network architecture that mirrors the structure and function of the human brain, simulating human-like thinking processes (14). This neural

architecture comprises interconnected neurons that function as sophisticated information systems, primarily designed to solve complex problems (15). AI, particularly through machine learning (ML) and deep learning (DL) models, has gained significant prominence in automating image interpretation and enhancing clinical decision-making, making it an invaluable tool in modern endodontics (16). ML models rely on statistical techniques to recognize patterns in data and adapt as new information becomes available (17), while DL utilizes intricate neural networks that emulate the brain's architecture to discern even the most subtle patterns in imaging data (18). Advancements, especially in convolutional neural networks (CNNs) and artificial neural networks (ANNs), enable AI models to analyze complex dental structures with remarkable precision (19,20).

One of AI's most significant contributions to endodontics is its ability to reduce variability between observers. Different clinicians may interpret the same CBCT data differently, but AI systems, once trained, provide standardized, objective assessments, thereby improving diagnostic reliability (21). Moreover, AI-driven models can pinpoint areas of concern, often identifying subtle pathologies that might be overlooked by human observers (22). This is particularly valuable in endodontics, where accurate diagnoses and precise treatment planning are essential to successful patient outcomes. One study demonstrated that AI systems achieved 96% accuracy rate in locating the minor apical constriction (23). These AI-based techniques not only reduce human error but also standardize the measurement process, resulting in more consistent and reliable outcomes compared to traditional manual methods (19).

Given the rapid advancements in AI and its integration with CBCT technology, it is crucial for endodontists to stay updated on AI-based CBCT applications. The primary aim of this review is to explore in detail how the combination of AI and CBCT enhances diagnostic accuracy and aids in more precise treatment planning in endodontics. Additionally, this review aims to highlight both the current applications and the potential future developments of AI technologies in endodontics, paving the way for more advanced

diagnostic tools and more effective treatment strategies in the field.

## Materials and Methods

This comprehensive review was conducted by identifying and compiling relevant literature through a comprehensive search of electronic databases, including Google Scholar, Semantic Scholar, Medline, PubMed, Embase, Web of Science, and Scopus. The search spanned publications from January 2000 to October 5, 2024, employing keywords such as “artificial intelligence”, “machine learning”, “deep learning”, “endodontics”, “CBCT”, “cone beam computer tomography”, “advanced analytics”, “computational linguistics”, “automation”, “intelligent agents”, “probabilistic reasoning”, “convolutional neural networks”, “artificial neural networks”, and “dentistry.” Full-text articles were targeted, and both manual and electronic searching techniques were employed to ensure exhaustive coverage. The selection process occurred in two stages. Initially, articles were screened based on their titles and abstracts for relevance to our research focus. This preliminary search identified 3,472 articles. After removing 603 duplicates, 2,869 articles were selected for further evaluation in the second stage.

In this review, the criteria for selecting appropriate papers included the following: (1) studies conducted in vitro, on animals, or in clinical settings, (2) research that utilized AI-based CBCT in endodontics, (3) studies focusing on root canal morphology, periapical lesions, root fractures, and the determination of working length, (4) full availability of articles, and (5) articles that were written in English and published in reputable, internationally indexed journals. The exclusion criteria consisted of: (1) studies that centered on AI applications in dentistry, but not specifically on AI-based CBCT in endodontics, (2) research on the effects of AI that did not involve root morphology, periapical lesions, root fractures, or assessments of working length, and (3) articles written in languages other than English. In total, 2072 articles were initially identified. However, 703 of these were duplicates, and 97 were excluded for various reasons. As a result, 37 original articles were included in this review. Figure 1 illustrates the flowchart of the article selection

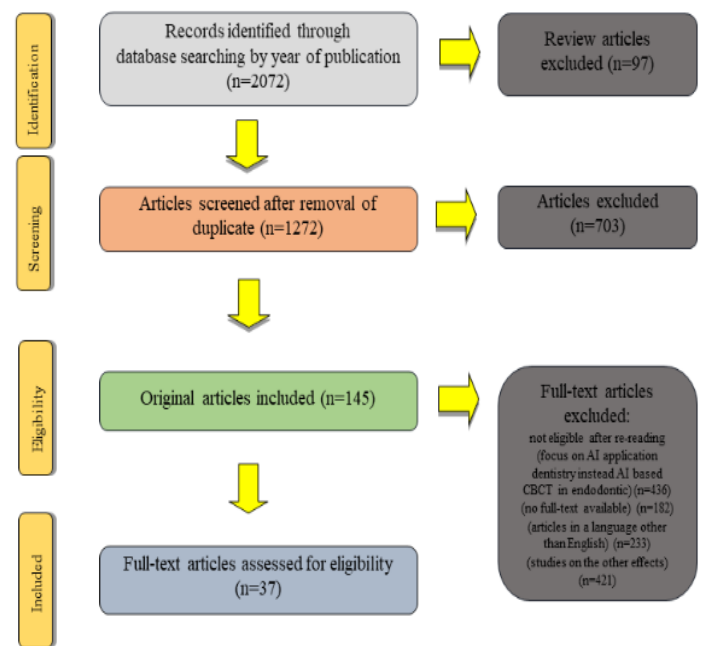
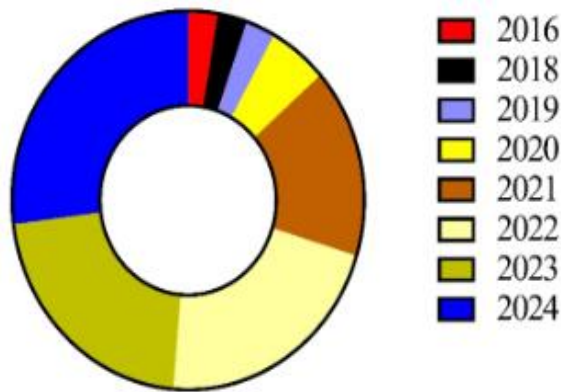


Figure 1. Searching and selecting articles flowchart

process for this review. To maintain objectivity during the critical analysis, the identities of the authors and article specifics were anonymized before being reviewed by a panel of two experts. Each selected article was meticulously reviewed to assess the progression of AI based CBCT trends in endodontics during the analyzed period.

## Results

In this comprehensive review, both quantitative and qualitative data from 37 research articles were analyzed. The majority of these studies were conducted over the past decade. Our search included articles dating back to the year 2000. However, research involving AI applications in CBCT within the field of endodontics began to emerge in the literature around 2016 (Figure 2). The research trends indicate a steady increase in studies related to AI-based CBCT in endodontics. Most of this research focused on verifying working lengths, identifying periapical pathologies, analyzing root canal morphologies, and detecting root fractures.



**Figure 2.** Trends in AI Applications in CBCT in Endodontics (2000-2024)

## Discussion

### 4.1- Root Canal Morphology with AI-Based CBCT

Root canal morphology, which varies greatly between patients and even among different teeth of the same patient, poses a significant challenge for clinicians aiming to achieve optimal treatment outcomes (24). The introduction of AI into CBCT analysis has revolutionized this process, providing enhanced accuracy, efficiency, and diagnostic capability (16). One of the primary applications of AI in endodontics is the automated detection and classification of complex root canal systems (4). Studies have highlighted the effectiveness of AI in identifying challenging root canal anatomies which are often difficult to locate using conventional techniques (5,18,25,26). The studies summarized in Table 1 clearly demonstrate that the integration of AI with CBCT significantly enhances the accuracy and efficiency in diagnosing root canal anatomies. The study of Fu et al. (2023) introduced a deep learning-based approach that successfully identified root canal configurations with high accuracy, utilizing a CNN model trained on a large dataset of annotated CBCT images (3). This AI system was able to distinguish between single, double, and fused root canal systems with minimal human intervention. Another significant contribution is demonstrated in the results of Albitar et al. where they employed a YOLOv5 architecture, designed for effective and efficient object detection, combined with U-Net models,

designed for semantic segmentation tasks in image processing, to segment and localize MB2 canals in maxillary molars automatically (27). The YOLOv5 architecture is integrated with U-Net models to enhance image processing capabilities. Their model achieved a sensitivity of over 90% in detecting these elusive canals, a notable improvement over traditional radiographic methods that often miss MB2 canals due to their subtle anatomical presentation. The success of these deep learning models in locating such challenging structures highlights the potential of AI-CBCT integration to enhance diagnostic precision and support more thorough root canal treatments (12). C-shaped root canals are particularly complex due to their unusual morphology and variability in shape across different teeth (28). This approach resulted in a classification accuracy of 87%, demonstrating a substantial improvement over the manual identification technique. Further advancements are seen utilizing micro-computed tomography (micro-CT) as a reference standard to train models (29). This AI system not only achieved superior segmentation accuracy but also provided a visual explanation of its decision-making process, enhancing clinicians' trust in AI-driven diagnostics (24). The inclusion of micro-CT-guided techniques offers a new benchmark for AI models, providing highly precise segmentation data that can be used to further refine CBCT-based diagnostics (30). By providing clinicians with both accurate results and insights into the AI's reasoning, this system facilitates a more informed decision-making process and fosters greater collaboration between human practitioners and AI technology. A study by Jeon et al. focused on the application of deep-learning models to predict C-shaped canals in mandibular second molars using panoramic radiographs and CBCT (26). Evidence showed that the AI model demonstrated a remarkable ability to predict C-shaped canals complex anatomies with high sensitivity and specificity (31). This technology not only aids in the preoperative planning of root canal treatments but also reduces the risk of missed canals, which can lead to treatment

**Table 1.** Assessment of root canal morphology using AI and CBCT technologies based on the evidence of clinical studies

Reference	Type of AI Used	AI architecture	Accuracy / Diagnostic Metrics	Outcome
Fu et al. (2023) (3)	Deep Learning	CNN	High Accuracy > 90%	Successful detection of complex root canal morphologies in premolars.
Albitar et al. (2022) (27)	Machine Learning	YOLO + 2D U-Net	High Sensitivity and Specificity	Improved detection and localization of MB2 canals in CBCT images.
Ibraheem (202) (70)	Deep Learning	C-ResNet	>90%	Effective identification of C-shaped canals in mandibular molars.
Yang et al. (2022) (29)	Explainable AI	CNN	High Accuracy	Improved classification accuracy for C-shaped canal recognition in dental radiographs.
Duman et al. (2024) (41)	Object Detection	YOLOv5	High Precision	Accurate segmentation of the second mesiobuccal canal in CBCT data.
Zhang et al. (2022) (28)	Deep Learning	Lightweight CNN	>90%	Efficient detection of C-shaped canals with reduced computational load.
Lin et al. (2021) (30)	Convolutional Network	CNN	Superior to Manual Segmentation	Enhanced segmentation of pulp cavities and dental structures.
Zhao et al. (2024) (32)	Machine Learning	PAINet and ResNet50/101/152	Improved Accuracy	Effective grading and severity assessment of apical periodontitis in CBCT scans.
Ezhov et al. (2021) (12)	AI / ML	CNN based on state-of-the-art	Clinically Relevant Accuracy	Comprehensive AI tool for enhanced diagnosis across complex dental cases.
Shaheen et al. (2021) (34)	Deep Learning	Multi-class CNN	High Diagnostic Accuracy	Enhanced accuracy in tooth segmentation and classification.
Hu et al. (2022) (35)	Deep Learning	R-CNN	High Sensitivity and Specificity	Accurate detection of anatomical root fractures in complex dental images.
Fontenele et al. (2022) (33)	Deep Learning	CNN with Augmented Data	High Accuracy	Validated segmentation tool regardless of root fillings and types.
Yang et al. (2023) (36)	Generative Models	GAN	Effective Enhancements	Successful augmentation and classification of C-shaped canals through GAN-generated data.
Htvani et al. (2018) (38)	Super-Resolution	CNN	Enhanced Resolution Quality	Improved visual clarity and diagnostic capability of CBCT images.
Yang et al. (2024) (4)	Object Detection	Multi-center Study	Consistent Across Centers	Successful external validation and consistency of AI models in diverse settings.
Ji et al. (2024) (7)	Resolution Enhancement	AI Optimization	Improved Image Quality	Successful optimization of CBCT resolution for enhanced diagnostic accuracy with minimal radiation exposure.
Wu et al. (2024) (2)	Deep Learning	CNN	Accurate Identification	Improved accuracy in identifying challenging fused-rooted structures.
Jeon et al. (2021) (26)	Predictive Models	CNN	High Accuracy	Effective prediction of C-shaped canals, assisting in improved treatment outcomes.
Wang et al. (2024) (25)	Multi-task Learning	CNN + Segmentation Models	High Planning Accuracy	Enhanced treatment planning through precise segmentation of complex dental anatomies.
Sherwood et al. (2021) (18)	Deep Learning	CNN	High Diagnostic Performance	Successful segmentation and classification of complex C-shaped canal morphologies.
Hiraiwa et al. (2019) (5)	Deep Learning	CNN	High Accuracy	Effective assessment of root morphology using advanced AI techniques.
Wu et al. (2024) (2)	Deep Learning	CNN	High Accuracy	Improved identification of fused-rooted molar structures through AI-assisted analysis of X-ray images.
Chen et al. (2024) (37)	Deep Learning	Sequential CNNs	Predictive Accuracy	Accurate prediction of complex dental treatment sequences, aiding in automated treatment planning based on historical data.

failures (29). The study by Wang et al. employed a deep-learning-based approach to classify C-shaped canal morphologies, incorporating a multi-task feature learning method that allows the system to perform segmentation and classification simultaneously (25). By leveraging the high-resolution capabilities of CBCT, this model successfully identified variations in C-shaped canals and provided clinicians with critical information needed for accurate treatment planning (29). Evidence explored how deep learning models could be applied to classify C-shaped canal morphologies in mandibular second molars (2,18). By combining CBCT imaging with deep learning algorithms, their system was able to detect C-shaped canals with remarkable precision, offering clinicians a valuable tool for treatment planning. These AI-driven models not only improved the accuracy of morphological classification but also allowed for a more efficient workflow, as the automation of the diagnostic process reduced the time required for interpretation (32).

The integration of AI with CBCT imaging extends beyond simple detection to include automated segmentation and classification of root canals and dental structures (33). The study by Shaheen et al. introduced a robust AI model capable of segmenting and classifying various dental and periodontal structures within CBCT scans (34). This system, based on a modified U-Net architecture, achieved a segmentation accuracy of 95.3% across multiple tooth classes and root canal types, demonstrating its potential to streamline both diagnosis and treatment planning. Lin et al. explored the use of micro-CT data to train an AI model for automatic segmentation of pulp cavities in CBCT images (30). By utilizing high-resolution micro-CT scans as ground truth, the authors were able to produce a highly accurate segmentation model that outperformed traditional CBCT interpretation methods. The resultant AI system was capable of delineating the intricate structures of pulp cavities and root canals with 97% accuracy, providing clinicians with a reliable tool for

assessing root canal morphology even in cases of severe calcification or structural anomalies.

The ability of the AI model to segment not only the tooth but also the individual canals opens up new possibilities for personalized treatment planning in endodontics (35). Another significant contribution in this area comes from Yang et al., who developed a generative adversarial network (GAN) to synthesize images for the classification of C-shaped root canals (36). This innovation is particularly noteworthy because it addresses a common limitation in AI model training: the lack of large, high-quality datasets. By creating synthetic data that closely resembles real-world cases, GAN-based models can train on more varied examples, improving their ability to generalize across different clinical scenarios (22). Furthermore, Chen et al. introduced an AI-based approach that applied a deep multi-task learning model to enhance root canal treatment planning (37). The system was designed to segment root canals automatically and provide an accurate assessment of the root canal system's complexity (16). Such models are particularly valuable in cases where irregular anatomy or radiopaque fillings may obscure the clinician's view (3). A noteworthy study by Wu et al. developed a deep-learning model that utilized CBCT images to identify root canal morphology in fused-rooted mandibular second molars. Their model was particularly effective in cases where root canal systems presented with irregular anatomical variations, achieving a level of accuracy that outperformed manual assessments by clinicians (2).

One of the limitations of CBCT imaging is the relatively low resolution compared to other imaging modalities, such as micro-CT (38). This can impact the ability to detect fine anatomical details, such as small canals or subtle fractures (39,40). To address this issue, Ji et al. applied deep learning-based super-resolution techniques to enhance the resolution of dental CBCT images (7). Their model used a CNN to increase the resolution of CBCT scans, thereby providing clearer images of root canal systems and other anatomical features. This

advancement is particularly important for detecting smaller root canals, such as second mesiobuccal (MB2) canals in maxillary molars, which are often difficult to visualize on standard-resolution CBCT scans (41). By applying super-resolution techniques, AI systems can help clinicians identify these critical anatomical features more reliably (38). Ji et al. explored an AI-based technique for optimizing CBCT resolution (7). The system employed a deep learning algorithm that improved the resolution of CBCT images, allowing for clearer visualizations of the root canal anatomy. This approach is particularly beneficial in identifying small anatomical details, such as accessory canals or minor fractures, which are often difficult to detect in lower-resolution scans (29). Additionally, this approach has the potential to reduce the need for higher radiation doses, as lower-resolution scans can be enhanced through AI-driven super-resolution algorithms, maintaining diagnostic accuracy while minimizing patient exposure to radiation (42).

### **3.2- Precision in Diagnosing Periapical Lesions with AI-Assisted CBCT Data**

Detecting periapical lesions through radiography poses significant challenges, even for experienced clinicians. Research indicates that to visualize a periapical radiolucency on a 2D radiograph, an average of 7.1% mineral bone loss or at least 12.5% cortical bone loss is necessary (43). Moreover, the interpretation of radiographs is often subjective (20). CBCT has demonstrated superior accuracy in diagnosing periapical lesions compared to traditional periapical radiographs. Campello and colleagues found that the sensitivity for detecting periapical lesions was only 28% with periapical radiographs, while it reached up to 73.6% with CBCT (44). However, analyzing CBCT volumes can be labor-intensive and time-consuming. Additionally, clinicians who are not specialized in oral radiology may miss subtle density variations in CBCT images, particularly in larger fields of view (13). To address these challenges, AI is being developed to assist clinicians in identifying periapical pathosis.

The use of AI-based diagnostic systems, particularly CNNs, has demonstrated remarkable advancements in detecting periapical lesions in CBCT scans (19). As outlined in the referenced studies, the diagnostic accuracy of AI models consistently surpasses traditional methods. For instance, Setzer et al. reported an impressive 93% accuracy and 88% specificity in detecting periapical lesions using AI models applied to CBCT data (20). In comparison, conventional radiographic techniques such as periapical radiographs, despite being widely used, exhibit a lower sensitivity, as demonstrated by Antony et al., where detection sensitivity for periapical and panoramic radiograph was 55% and 28%, respectively (45). These findings, summarized in Table 2, underscore the enhanced diagnostic capability of AI, particularly in identifying subtle or hidden lesions that may otherwise be missed through manual interpretation.

In addition to diagnostic accuracy, AI systems significantly improve the efficiency of clinical workflows by automating the analysis of complex CBCT images. Studies such as Ezhov et al. and Orhan et al. highlight that AI algorithms are capable of real-time lesion classification and segmentation, significantly reducing the time required for manual image review by clinicians (10,12). This reduction in time is particularly beneficial in high-volume clinical settings or areas with limited access to radiological expertise, as AI models can provide rapid and reliable diagnostic support (20). As seen in Table 1, the implementation of AI in the diagnostic workflow not only accelerates the identification of periapical lesions but also enhances diagnostic precision, ensuring that treatment plans are both timely and accurate (10,12,20,21,27,46,47).

Furthermore, AI's role extends beyond diagnosis, contributing to improved endodontic treatment planning and outcome prediction. Recent studies, such as Qu et al., demonstrate AI's capability to predict the success of endodontic surgeries with up to 80% accuracy (17). This predictive power is crucial in clinical decision-making, allowing practitioners to base

**Table 2.** Diagnosis of periapical lesions using AI and CBCT technologies based on the evidence of clinical studies

Reference	Type of AI used	AI architecture	Accuracy / Diagnostic Metrics	Outcome
Setzer et al. (2020) (20)	Deep Learning (CNNs)	Utilizes convolutional neural networks for classifying   periapical lesions based on CBCT images.	93% accuracy, 88% specificity	Accuracy = 0.93 with specificity = 0.88, positive predictive value = 0.87, negative predictive value = 0.93, and cumulative Deep Learning segmentation index = 0.67
Albitar et al. (2022) (27)	Deep Learning	Recognizing patterns in imaging data to locate mesial buccal 2 canals in endodontics.	Sensitivity of 92% reported in clinical validations	Sensitivity = 0.8, a specificity = 1, PPV = 1, and a NPV = 0.83, accuracy = 0.9, and segmentation performance of unobturated mesial buccal canals = 0.3018
Fu et al. (2024) (21)	3D Convolutional Neural Networks (PAL-Net)	Segmentation and analysis of 3D volumetric images for detailed evaluation of periapical lesions.	Accuracy over 90% compared to specialists	Operating characteristic curve = 0.98 and average Dice similarity Coefficient = 0.87
Ezhov et al. (2021) (12)	Hybrid AI Techniques	Combines classical image processing with machine learning for enhanced diagnostics.	Specific accuracy metrics closely evaluated, not quantified	Sensitivity = 0.8537, specificity = 0.9672, reducing the time required for manual review by clinicians, and improving workflow efficiency.
Kazimierczak et al. (2024) (46)	Multiple Machine Learning Models	Evaluates varying algorithms for diagnostic precision in endodontic treatments.	Verified accuracy rate of ~94% based on expert analysis	Improves treatment planning by providing accurate diagnostics, contributing to better patient outcomes and reduced retreatment rates.
Orhan et al. (2020) (10)	Deep Learning (CNNs)	Implements CNNs for automated detection of pathosis from CBCT scans.	Reported accuracy around 90%.	Facilitates quicker identification of pathosis, reducing diagnostic turnaround times and enabling more timely interventions.
Kazimierczak et al. (2024) (47)	AI-Based Analysis	Evaluates AI models for diagnostic purposes using both imaging types.	CBCT significantly outperformed traditional methods.	Highlights the potential of AI in enhancing the diagnostic accuracy of CBCT over panoramic radiography, supporting the integration of AI for more reliable results.

their treatment strategies on data-driven insights. Additionally, AI has shown high precision in determining working lengths during root canal treatments. As outlined in Latke et al., AI algorithms achieved an accuracy of 86.51% in measuring root canal lengths, reducing the margin of human error and improving overall treatment outcomes (23). This integration of AI into endodontic practice not only ensures better patient care but also paves the way for more personalized and accurate treatment approaches (42). Looking ahead, AI might advance to a point where it can

clinicians about potential apical pathosis and other odontogenic or non-odontogenic lesions present in the images (10). This capability would be especially beneficial in regions where access to oral radiologists and appropriate radiology training is limited (20).

### 3.3- Detection of Vertical Root Fractures with AI-Based CBCT

The accurate identification of vertical root fractures (VRFs) presents a critical challenge in endodontics, often leading to diagnostic ambiguity and potential treatment errors (48). Traditional radiographic methods, particularly



2D radiography, have inherent limitations, such as the inability to provide clear images of fractures due to overlapping structures and a lack of depth perception (49). As a result, VRFs can remain undetected, or their diagnosis can be delayed until more advanced symptoms appear (50). This has prompted clinicians to turn to CBCT, which offers 3D-imaging and enhanced resolution that significantly improves the detection rates of VRFs (51,52).

Several studies have explored the effectiveness of CBCT in diagnosing vertical root fractures (51,53,54). The study of Edlund et al. highlights that CBCT significantly outperforms traditional radiographs in identifying fractures, especially in endodontically treated teeth (55). This study suggests that the superior imaging capability of CBCT makes it a critical tool for early diagnosis, with higher sensitivity and specificity rates. However, despite the clear advantages of CBCT, analyzing these complex volumetric datasets remains time-consuming and requires specialized expertise, often limiting its widespread adoption in routine clinical practice (11,56). The studies summarized in Table 3 clearly demonstrate that the integration of AI with CBCT significantly enhances the accuracy and efficiency in diagnosing VRFs, alleviating the diagnostic burden on clinicians and improving early detection rates.

The introduction of AI, particularly deep learning models, has revolutionized the detection of VRFs by automating the interpretation of CBCT images. Research such as Yang et al. that AI algorithms, specifically CNNs, have shown remarkable potential in diagnosing VRFs with high accuracy (57). These algorithms are trained on vast datasets of annotated CBCT images and are capable of detecting subtle fracture patterns that may be missed by the human eye, even in complex cases involving multirooted teeth. Furthermore, Chang et al. (2016) asserts in their systematic review that there is evidence supporting the efficacy of CBCT combined with AI (6). This review emphasizes that AI systems trained to detect fractures in CBCT images have demonstrated diagnostic accuracies exceeding 90%, with some studies reporting near-perfect specificity.

The ability of AI to consistently outperform traditional diagnostic methods, particularly in cases where fractures are minute or obscured, highlights its transformative role in endodontic practice (58).

Moreover, the study Alaugaily et al. provides insight into the radiographic indicators that correlate with VRFs, such as bone loss patterns and the widening of the periodontal ligament space (52). These patterns serve as critical predictors that AI systems can be trained to recognize, further enhancing the diagnostic power of CBCT imaging. The identification of these subtle radiographic features enables early detection of fractures, which is crucial for timely intervention and the preservation of affected teeth (9). As AI continues to evolve, its integration into endodontic diagnostics extends beyond fracture detection (42). Emerging deep learning models are also being utilized to predict treatment outcomes, as demonstrated in the study Hu et al (35). This study explores the potential of AI to not only detect fractures but also assist in predicting the prognosis of affected teeth, offering valuable insights into treatment planning. By incorporating AI-based predictions into clinical decision-making, endodontists can develop more precise, personalized treatment strategies that enhance patient outcomes (59). Enhancing the accuracy of AI in diagnosing VRF can prevent the unnecessary treatment of non-restorable teeth and the unwarranted extraction of healthy teeth that have been incorrectly identified (60).

### **3.4- Determination of Working Length with AI-Based CBCT**

Accurate determination of working length (WL) is a critical aspect of endodontic treatment, as it directly influences the success of root canal procedures (61). Traditional techniques, such as tactile sensation, radiographic imaging, and electronic apex locators (EALs), have been employed for decades. While these methods have been the foundation of WL determination, they often suffer from limitations, particularly in precision and consistency, when dealing with complex root canal anatomies (62). Radiographs provide 2D representations, which may result in inaccuracies due to anatomical

**Table 3.** Diagnosis of vertical root fractures using AI and CBCT technologies based on the evidence of clinical and preclinical studies

Reference	Objective	AI architecture	Outcome	Accuracy / Diagnostic Metrics	Implications
<b>Yang et al 2023 (57)</b>	Examine AI application in detecting VRFs with CBCT	Use of CNNs trained on annotated CBCT images	AI significantly enhances accuracy, sensitivity (93%), and specificity (100%) in identifying VRFs	93% sensitivity, 100% specificity	AI automates diagnosis, reduces interpretative burden on clinicians, streamlining workflow
<b>Alaugaily et al 2022 (52)</b>	Investigate predictors correlating with VRFs in CBCT images	AI models (machine learning) analyze bone loss patterns and ligament space widening to correlate with the presence of vertical root fractures.	Radiographic indicators provide critical diagnostic clues that AI models can be trained to recognize	-	Enables early detection and intervention, preserving tooth structure
<b>Hu et al 2022 (35)</b>	AI's role in not only detecting but predicting treatment outcomes	Deep learning analysis of CBCT images used for both tasks	AI aids in prognosis prediction, enhancing personalized treatment strategies	-	Encourages integration of AI in clinical decision making for better patient outcomes
<b>Chang et al 2016 (6)</b>	Systematic review of CBCT's effectiveness in vrf detection	Focusing on various machine learning models for VRF detection.	AI-CBCT systems have diagnostic accuracies exceeding 90%, outperforming traditional methods	>90% diagnostic accuracy in most studies	Highlights AI's transformative role in endodontic diagnostics and decision making

superimpositions (63), while EALs can be affected by variables such as moisture or the presence of metallic restorations (8).

The advent of CBCT and AI has significantly improved the accuracy and efficiency of WL determination, offering clinicians powerful tools for more predictable outcomes (64). CBCT imaging provides high-resolution, three-dimensional insights into root canal structures, enabling more precise measurement of WL (65). However, the challenge lies in the time-consuming and complex task of interpreting these volumetric datasets. This is where AI proves invaluable by automating the analysis, ensuring higher diagnostic precision while reducing human error (66). AI-based CBCT systems, utilizing CNNs, can detect anatomical landmarks such as the root canal entrance and apex with impressive accuracy. By training these models on large,

automate the process of WL determination (7,22). Recent studies have demonstrated that AI can achieve an accuracy of up to 96% in determining working length from CBCT images, making it a reliable alternative to traditional methods (23). This enhanced precision not only reduces the likelihood of over- or under-instrumentation but also significantly contributes to better treatment outcomes by ensuring optimal cleaning and shaping of the root canals (22).

AI systems have also been shown to outperform traditional methods, achieving accuracy rates as high as 100% in some instances, particularly in cases where complex root morphologies complicate manual measurement (67). By processing large amounts of CBCT data, AI models provide real-time, standardized measurements that eliminate the subjectivity associated with tactile sensation or

2D-radiographic interpretation (68). As a result, AI enhances both the efficiency and consistency of WL determination, leading to more predictable clinical outcomes.

The integration of AI into endodontics also extends beyond accurate WL determination. Sherwood et al., have shown that AI significantly improves diagnostic accuracy, especially in cases involving anatomical variations or difficult-to-access apices (18). In contrast to EALs, which rely on favorable canal conditions and can be influenced by operative variables, AI offers a standardized approach with a learning component that continuously improves its precision over time. This is particularly advantageous in challenging anatomies, such as S-shaped or severely curved canals, where AI's ability to perform geometric analysis through high-dimensional image processing proves invaluable, reducing the incidence of both over-instrumentation and under-instrumentation (1,69). Moreover, AI's role in endodontics is not limited to diagnostics but also extends to prognostics (16). Karobari et al. highlights how AI can integrate both diagnostic data (e.g., WL determination) and prognostic factors (e.g., periapical health) to provide a comprehensive assessment of treatment success (15). Such predictive models are becoming increasingly valuable as personalized treatment planning gains traction in endodontics, allowing for more tailored interventions that enhance patient outcomes (14).

### 3.5- Clinical Impact and Future Directions

The integration of AI into CBCT imaging is significantly impacting the field of endodontics, particularly in enhancing diagnostic accuracy and improving treatment planning. Such advances not only improve patient outcomes but also reduce unnecessary exploratory procedures, leading to greater patient comfort and lower treatment costs. The successful implementation of such AI systems highlights the potential of these technologies to revolutionize patient care by increasing efficiency and diagnostic precision. AI-driven CBCT systems also hold great promise for automating the detection and segmentation of

complex root canal morphologies. This automation reduces the likelihood of missed canals, incomplete treatments, and ultimately, failed procedures. By delivering detailed, real-time insights into complex root canal structures, these systems are improving predictability and treatment success.

An additional benefit of AI advancements in endodontics is the development of explainable AI models. These models address a significant barrier to clinical adoption (trust and interpretability). Clinicians are more likely to embrace AI technologies when they can understand how the system arrives at its conclusions. Therefore, explainable AI makes it easier for clinicians to validate the AI's recommendations, ensuring they align with their clinical judgment. However, despite the considerable progress, challenges remain. Ensuring the generalizability of AI models across various patient demographics and different CBCT equipment is crucial. Future research needs to focus on creating more adaptable AI systems that can function across diverse populations and equipment. AI in CBCT imaging offers a promising future for endodontics, particularly in diagnosing and managing complex root canal morphologies. By automating tasks like segmentation and diagnosis, AI not only improves treatment planning but also reduces errors and enhances patient care. As this technology evolves, it is expected to lead to more personalized, accurate, and efficient endodontic treatments, ultimately transforming the field.

### 3.6- Limitations and Challenges

A significant challenge in implementing AI in endodontics is the quality and volume of training data. AI models, particularly deep learning algorithms, require extensive, well-annotated datasets, but such data are scarce in endodontics, especially for rare root canal anatomies like C-shaped or fused-root canals. Inconsistent imaging protocols and CBCT settings among practices further complicate this, affecting the AI models' ability to generalize effectively. Generalizability remains a key obstacle, as models that perform well in controlled environments may struggle in

real-world clinical contexts. Additionally, the interpretability of AI decisions is another hurdle; many deep learning models operate as “black boxes,” providing minimal transparency about their decision-making processes. This opacity can limit clinicians’ trust and acceptance, highlighting the need for advancements in explainable AI to enhance clinical reliability. Regulatory and ethical issues also create barriers. Current regulations for AI in dentistry are underdeveloped, leading to uncertainties regarding safety standards and accountability for errors, whether by clinicians, developers, or manufacturers. Integration into existing workflows presents additional difficulties, requiring compatibility with diverse CBCT machines, dental software, and electronic health records, alongside the need for substantial infrastructure and clinician training. Cost and accessibility are other notable challenges, particularly for smaller practices unable to afford advanced imaging systems and computing infrastructure. Lastly, AI’s reliance on patient data raises significant privacy concerns, necessitating strict protocols for data security, especially when using cloud-based platforms for analysis.

### Conclusion

The incorporation of AI into CBCT imaging has significantly transformed endodontic diagnostics and treatment planning. AI, through deep learning models, has demonstrated superior accuracy in detecting, classifying, and segmenting complex root canal anatomies, such as C-shaped and MB2 canals, which are often missed by traditional imaging methods. Additionally, AI-assisted CBCT’s keys contributions are in diagnosis of periapical lesions, determination of working length, and detection of vertical root fractures, which are difficult to diagnose with traditional imaging methods, improving the quality of treatments. In conclusion, AI-based CBCT imaging is revolutionizing endodontic practices by offering clinicians enhanced tools for more accurate diagnostics and effective treatment planning. As AI technologies continue to evolve, their integration into endodontics will result in more

personalized, efficient, and predictable treatment outcomes, setting the stage for future advancements in patient care.

### Funding Information

The authors confirm that the study received no funding.

### Conflict of Interest Statement

The authors confirm they have no conflict of interest.

### Acknowledgment

The authors would like to express their sincere gratitude to Arman Abroumand Gholami for his valuable assistance and insightful guidance in the preparation and revision of this manuscript.

### References

1. Sakkir N, Thaha KA, Nair MG, Joseph S, Christalin R. Management of dilacerated and S-shaped root canals-an endodontist’s challenge. *J Clin diagnostic Res JCDR*. 2014;8(6):ZD22.
2. Wu W, Chen S, Chen P, Chen M, Yang Y, Gao Y, et al. Identification of Root Canal Morphology in Fused-rooted Mandibular Second Molars From X-ray Images Based on Deep Learning. *J Endod [Internet]*. 2024;50(9):1289-1297.e1. Available from: <https://www.sciencedirect.com/science/article/pii/S0099239924003388>
3. Fu D, Shi K, Wu F, Zhu F, Zhu H. An artificial intelligence system for detecting the root canal morphology of the mandibular first premolar on panoramic radiographs. 2023;
4. Yang S, Kim KD, Kise Y, Nozawa M, Mori M, Takata N, et al. External Validation of the Effect of the Combined Use of Object Detection for the Classification of the C-Shaped Canal Configuration of the Mandibular Second Molar in Panoramic Radiographs: A Multicenter Study. *J Endod [Internet]*. 2024;50(5):627–36. Available from: <https://www.sciencedirect.com/science/article/pii/S0099239924000657>.
5. Hiraiwa T, Arijji Y, Fukuda M, Kise Y, Nakata K, Katsumata A, et al. A deep-learning artificial intelligence system for assessment of root morphology of the mandibular first molar on panoramic radiography. *Dentomaxillofacial Radiol*. 2019;48(3):20180218.

6. Chang E, Lam E, Shah P, Azarpazhooh A. Cone-beam Computed Tomography for Detecting Vertical Root Fractures in Endodontically Treated Teeth: A Systematic Review. *J Endod* [Internet]. 2016;42(2):177–85. Available from: <https://www.sciencedirect.com/science/article/pii/S0099239915009036>
7. Ji Y, Chen Y, Liu G, Long Z, Gao Y, Huang D, et al. Construction and evaluation of an AI-based CBCT resolution optimization technique for extracted teeth. *J Endod*. 2024;
8. Cardoso IV, Silveira MPC, Vitali FC, Piasecki L, da Fonseca Roberti Garcia L, Bortoluzzi EA, et al. Evaluation of changes in root canal length and accuracy of the electronic apex locator during different stages of endodontic treatment and retreatment. *Odontology*. 2024;112(2):537–45.
9. Patel S, Bhuva B, Bose R. Present status and future directions: vertical root fractures in root filled teeth. *Int Endod J*. 2022;55:804–26.
10. Orhan K, Bayrakdar IS, Ezhov M, Kravtsov A, Özyürek T. Evaluation of artificial intelligence for detecting periapical pathosis on cone-beam computed tomography scans. *Int Endod J*. 2020; 53(5):680–9.
11. Fan W, Zhang J, Wang N, Li J, Hu L. The application of deep learning on CBCT in dentistry. *Diagnostics*. 2023;13(12):2056.
12. Ezhov M, Gusarev M, Golitsyna M, Yates JM, Kushnerev E, Tamimi D, et al. Clinically applicable artificial intelligence system for dental diagnosis with CBCT. *Sci Rep*. 2021;11(1):15006.
13. Xiang B, Lu J, Yu J. Evaluating Tooth Segmentation Accuracy and Time Efficiency in CBCT Images using Artificial Intelligence: A Systematic Review and Meta-analysis. *J Dent*. 2024;105064.
14. Sadegh-Zadeh SA, Bagheri M. Harnessing the power of clinical data in dentistry: Importance and guidelines for dentists in AI modelling for enhanced patient care. *Open J Clin Med Images*. 2024; 4(1): 1188.
15. Karobari MI, Adil AH, Basheer SN, Murugesan S, Savadamoorthi KS, Mustafa M, et al. Evaluation of the diagnostic and prognostic accuracy of artificial intelligence in endodontic dentistry: A comprehensive review of literature. *Comput Math Methods Med*. 2023;2023(1):7049360.
16. Aminoshariae A, Kulild J, Nagendrababu V. Artificial intelligence in endodontics: current applications and future directions. *J Endod*. 2021; 47(9):1352–7.
17. Qu Y, Lin Z, Yang Z, Lin H, Huang X, Gu L. Machine learning models for prognosis prediction in endodontic microsurgery. *J Dent*. 2022;118:103947.
18. Sherwood AA, Sherwood AI, Setzer FC, Shamili J V, John C, Schwendicke F. A deep learning approach to segment and classify C-shaped canal morphologies in mandibular second molars using cone-beam computed tomography. *J Endod*. 2021; 47(12):1907–16.
19. Kirnbauer B, Hadzic A, Jakse N, Bischof H, Stern D. Automatic detection of periapical osteolytic lesions on cone-beam computed tomography using deep convolutional neuronal networks. *J Endod*. 2022;48(11):1434–40.
20. Setzer FC, Shi KJ, Zhang Z, Yan H, Yoon H, Mupparapu M, et al. Artificial Intelligence for the Computer-aided Detection of Periapical Lesions in Cone-beam Computed Tomographic Images. *J Endod* [Internet]. 2020;46(7):987–93. Available from: <https://www.sciencedirect.com/science/article/pii/S0099239920302351>
21. Fu WT, Zhu QK, Li N, Wang YQ, Deng SL, Chen HP, et al. Clinically oriented CBCT periapical lesion evaluation via 3D CNN algorithm. *J Dent Res*. 2024; 103(1):5–12.
22. Asgary S. Artificial Intelligence in Endodontics: A Scoping Review. *Iran Endod J*. 2024;19(2):85.
23. Latke V. Measuring Endodontic Working Length Using Artificial Intelligence. *Front Heal Informatics*. 2024;13(2):83–96.
24. Ramezanzade S, Laurentiu T, Bakhshandah A, Ibragimov B, Kvist T, EndoReCo, et al. The efficiency of artificial intelligence methods for finding radiographic features in different endodontic treatments-a systematic review. *Acta Odontol Scand*. 2023;81(6):422–35.
25. Wang Y, Xia W, Yan Z, Zhao L, Bian X, Liu C, et al. Root canal treatment planning by automatic tooth and root canal segmentation in dental CBCT with deep multi-task feature learning. *Med Image Anal* [Internet]. 2023;85:102750. Available from: <https://www.sciencedirect.com/science/article/pii/S1361841523000117>.
26. Jeon SJ, Yun JP, Yeom HG, Shin WS, Lee JH, Jeong SH, et al. Deep-learning for predicting C-shaped canals in mandibular second molars on panoramic radiographs. *Dentomaxillofac Radiol*. 2021; 50

- (5):20200513.
27. Albitar L, Zhao T, Huang C, Mahdian M. Artificial intelligence (AI) for detection and localization of unobturated second mesial buccal (MB2) canals in cone-beam computed tomography (CBCT). *Diagnostics*. 2022;12(12):3214.
28. Zhang L, Xu F, Li Y, Zhang H, Xi Z, Xiang J, et al. A lightweight convolutional neural network model with receptive field block for C-shaped root canal detection in mandibular second molars. *Sci Rep*. 2022;12(1):17373.
29. Yang S, Lee H, Jang B, Kim KD, Kim J, Kim H, et al. Development and validation of a visually explainable deep learning model for classification of C-shaped canals of the mandibular second molars in periapical and panoramic dental radiographs. *J Endod*. 2022;48(7):914–21.
30. Lin X, Fu Y, Ren G, Yang X, Duan W, Chen Y, et al. Micro-computed tomography-guided artificial intelligence for pulp cavity and tooth segmentation on cone-beam computed tomography. *J Endod*. 2021;47(12):1933–41.
31. Khanagar SB, Alfadley A, Alfouzan K, Awawdeh M, Alaqla A, Jamleh A. Developments and performance of artificial intelligence models designed for application in endodontics: A systematic review. *Diagnostics*. 2023;13(3):414.
32. Zhao T, Wu H, Leng D, Yao E, Gu S, Yao M, et al. An artificial intelligence grading system of apical periodontitis in cone-beam computed tomography data. *Dentomaxillofacial Radiol*. 2024;53(7):447–58.
33. Fontenele RC, do Nascimento Gerhardt M, Pinto JC, Van Gerven A, Willems H, Jacobs R, et al. Influence of dental fillings and tooth type on the performance of a novel artificial intelligence-driven tool for automatic tooth segmentation on CBCT images—A validation study. *J Dent*. 2022; 119: 104069.
34. Shaheen E, Leite A, Alqahtani KA, Smolders A, Van Gerven A, Willems H, et al. A novel deep learning system for multi-class tooth segmentation and classification on cone beam computed tomography. A validation study. *J Dent*. 2021; 115: 103865.
35. Hu Z, Cao D, Hu Y, Wang B, Zhang Y, Tang R, et al. Diagnosis of in vivo vertical root fracture using deep learning on cone-beam CT images. *BMC Oral Health*. 2022;22(1):382.
36. Yang S, Kim KD, Arijji E, Takata N, Kise Y. Evaluating the performance of generative adversarial network-synthesized periapical images in classifying C-shaped root canals. *Sci Rep*. 2023; 13 (1):18038.
37. Chen H, Liu P, Chen Z, Chen Q, Wen Z, Xie Z. Predicting sequenced dental treatment plans from electronic dental records using deep learning. *Artif Intell Med [Internet]*. 2024;147:102734. Available from: <https://www.sciencedirect.com/science/article/pii/S0933365723002488>.
38. Hatvani J, Horváth A, Michetti J, Basarab A, Kouamé D, Gyöngy M. Deep learning-based super-resolution applied to dental computed tomography. *IEEE Trans Radiat Plasma Med Sci*. 2018;3(2):120–8.
39. Mohammad-Rahimi H, Vinayahalingam S, Mahmoudinia E, Soltani P, Bergé SJ, Krois J, et al. Super-resolution of dental panoramic radiographs using deep learning: a pilot study. *Diagnostics*. 2023; 13(5):996.
40. Hwang JJ, Jung YH, Cho BH, Heo MS. Very deep super-resolution for efficient cone-beam computed tomographic image restoration. *Imaging Sci Dent*. 2020;50(4):331.
41. Duman ŞB, Çelik Özen D, Bayrakdar IŞ, Baydar O, Alhaija ESA, Helvacioğlu Yiğit D, et al. Second mesiobuccal canal segmentation with YOLOv5 architecture using cone beam computed tomography images. *Odontology*. 2024;112(2):552–61.
42. Ourang SA, Sohrabniya F, Mohammad-Rahimi H, Dianat O, Aminoshariae A, Nagendrababu V, et al. Artificial intelligence in endodontics: Fundamental principles, workflow, and tasks. *Int Endod J*. 2024;
43. Lai G, Dunlap C, Gluskin A, Nehme WB, Azim AA. Artificial intelligence in endodontics. *J Calif Dent Assoc*. 2023;51(1):2199933.
44. Campello AF, Gonçalves LS, Guedes FR, Marques FV. Cone-beam computed tomography versus digital periapical radiography in the detection of artificially created periapical lesions: A pilot study of the diagnostic accuracy of endodontists using both techniques. *Imaging Sci Dent*. 2017;47(1):25–31.
45. Antony DP, Thomas T, Nivedhitha MS. Two-dimensional periapical, panoramic radiography versus three-dimensional cone-beam computed tomography in the detection of periapical

- lesion after endodontic treatment: A systematic review. *Cureus*. 2020;12(4).
46. Kazimierczak W, Kazimierczak N, Issa J, Wajer R, Wajer A, Kalka S, et al. Endodontic Treatment Outcomes in Cone Beam Computed Tomography Images-Assessment of the Diagnostic Accuracy of AI. *J Clin Med*. 2024 Jul;13(14).
47. Kazimierczak W, Wajer R, Wajer A, Kiian V, Kloska A, Kazimierczak N, et al. Periapical Lesions in Panoramic Radiography and CBCT Imaging—Assessment of AI's Diagnostic Accuracy. *J Clin Med*. 2024;13(9):2709.
48. Quintero-Álvarez M, Bolaños-Alzate LM, Villa-Machado PA, Restrepo-Restrepo FA, Tobón-Arroyave SI. In vivo detection of vertical root fractures in endodontically treated teeth: Accuracy of cone-beam computed tomography and assessment of potential predictor variables. *J Clin Exp Dent*. 2021;13(2):e119.
49. Buitenhuis MB, Weinberg FM, Bielevelt F, Gilijamse M, Forouzanfar T, Speksnijder CM, et al. Anatomical position of the mandibular condyle after open versus closed treatment of unilateral fractures: A three-dimensional analysis. *J Cranio-Maxillofacial Surg*. 2023;51(11):682–91.
50. Mizuhashi F, Watarai Y, Ogura I. Diagnosis of vertical root fractures in endodontically treated teeth by cone-beam computed tomography. *J imaging*. 2022;8(3):51.
51. PradeepKumar AR, Shemesh H, Nivedhitha MS, Hashir MMJ, Arockiam S, Maheswari TNU, et al. Diagnosis of vertical root fractures by cone-beam computed tomography in root-filled teeth with confirmation by direct visualization: A systematic review and meta-analysis. *J Endod*. 2021; 47(8): 1198–214.
52. Alaugaily I, Azim AA. CBCT patterns of bone loss and clinical predictors for the diagnosis of cracked teeth and teeth with vertical root fracture. *J Endod*. 2022;48(9):1100–6.
53. de Lima KL, Silva LR, de Paiva Prado TB, Silva MAG, de Freitas Silva BS, Yamamoto-Silva FP. Influence of the technical parameters of CBCT image acquisition on vertical root fracture diagnosis: a systematic review and meta-analysis. *Clin Oral Investig*. 2023;27(2):433–74.
54. Habibzadeh S, Ghoncheh Z, Kabiri P, Mosaddad SA. Diagnostic efficacy of cone-beam computed tomography for detection of vertical root fractures in endodontically treated teeth: a systematic review. *BMC Med Imaging*. 2023;23(1):68.
55. Edlund M, Nair MK, Nair UP. Detection of Vertical Root Fractures by Using Cone-beam Computed Tomography: A Clinical Study. *J Endod* [Internet]. 2011;37(6):768–72. Available from: <https://www.sciencedirect.com/science/article/pii/S0099239911002548>
56. Zheng Z, Yan H, Setzer FC, Shi KJ, Mupparapu M, Li J. Anatomically constrained deep learning for automating dental CBCT segmentation and lesion detection. *IEEE Trans Autom Sci Eng*. 2020; 18(2): 603–14.
57. Yang P, Guo X, Mu C, Qi S, Li G. Detection of vertical root fractures by cone-beam computed tomography based on deep learning. *Dentomaxillofacial Radiol*. 2023;52(3):20220345.
58. Hung K, Yeung AWK, Tanaka R, Bornstein MM. Current applications, opportunities, and limitations of AI for 3D imaging in dental research and practice. *Int J Environ Res Public Health*. 2020;17(12):4424.
59. Semerci ZM, Yardımcı S. Empowering Modern Dentistry: The Impact of Artificial Intelligence on Patient Care and Clinical Decision Making. *Diagnostics*. 2024;14(12):1260.
60. Ahluwalia A, Gautam A, Thakar SS. Advanced Dentistry: Transforming Patient Care with Artificial Intelligence. *J Dent*. 2023;15(2):64–9.
61. ElAyouti A, Connert T, Dummer P, Löst C. A critical analysis of research methods and experimental models to study working length determination and the performance of apex locators—A narrative review with recommendations for the future. *Int Endod J*. 2022;55:281–94.
62. Mathew J. Root Canal Working Length Determination Using Digital Radiography, Electronic Apex Locator and Cone-Beam Computed Tomography—A Comparative Clinical Study. *Rajiv Gandhi University of Health Sciences (India)*; 2020.
63. Heinz J, Stewart K, Ghoneima A. Evaluation of two-dimensional lateral cephalogram and three-dimensional cone beam computed tomography superimpositions: a comparative study. *Int J Oral Maxillofac Surg*. 2019;48(4):519–25.
64. Surlari Z, Budală DG, Lupu CI, Stelea CG, Butnaru OM, Luchian I. Current Progress and challenges of using artificial intelligence in clinical dentistry—A Narrative review. *J Clin Med*. 2023;12(23):7378.
65. Kaur K, Saini RS, Vaddamanu SK, Bavabeedu SS,

- Gurumurthy V, Sainudeen S, et al. Exploring Technological Progress in Three-Dimensional Imaging for Root Canal Treatments: A Systematic Review. *Int Dent J*. 2024;
66. Habuza T, Navaz AN, Hashim F, Alnajjar F, Zaki N, Serhani MA, et al. AI applications in robotics, diagnostic image analysis and precision medicine: Current limitations, future trends, guidelines on CAD systems for medicine. *Informatics Med Unlocked*. 2021;24:100596.
67. Boreak N. Effectiveness of artificial intelligence applications designed for endodontic diagnosis, decision-making, and prediction of prognosis: a systematic review. *J Contemp Dent Pr*. 2020; 21(8): 926–34.
68. Bhat SH, Hareesh KS, Kamath AT, Kudva A, Vineetha R, Nair A. A Framework to Enhance the Experience of CBCT Data in Real-Time Using Immersive Virtual Reality: Impacting Dental Pre-Surgical Planning. *IEEE Access*. 2024;
69. Qu Y, Wen Y, Chen M, Guo K, Huang X, Gu L. Predicting case difficulty in endodontic microsurgery using machine learning algorithms. *J Dent*. 2023;133:104522.
70. Ibraheem WI. Accuracy of Artificial Intelligence Models in Dental Implant Fixture Identification and Classification from Radiographs: A Systematic Review. *Diagnostics*. 2024;14(8):806.